

Contents

Basic Anatomy of the Eye	1
Cornea and Sclera	4
Neuro-ophthalmology	12
Squint	23
Lens	32
Glaucoma	42
Optics and Refraction	50
Retina	58
Eyelids and Orbit	69
Conjunctiva and Community Ophthalmology	73

BASIC ANATOMY OF EYE

----- Active space -----

General Features

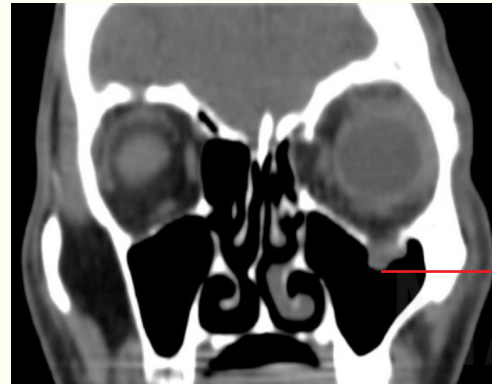00:01:23

Shape : Aspherical (Oblate spheroid).

Volume : 6 mL.

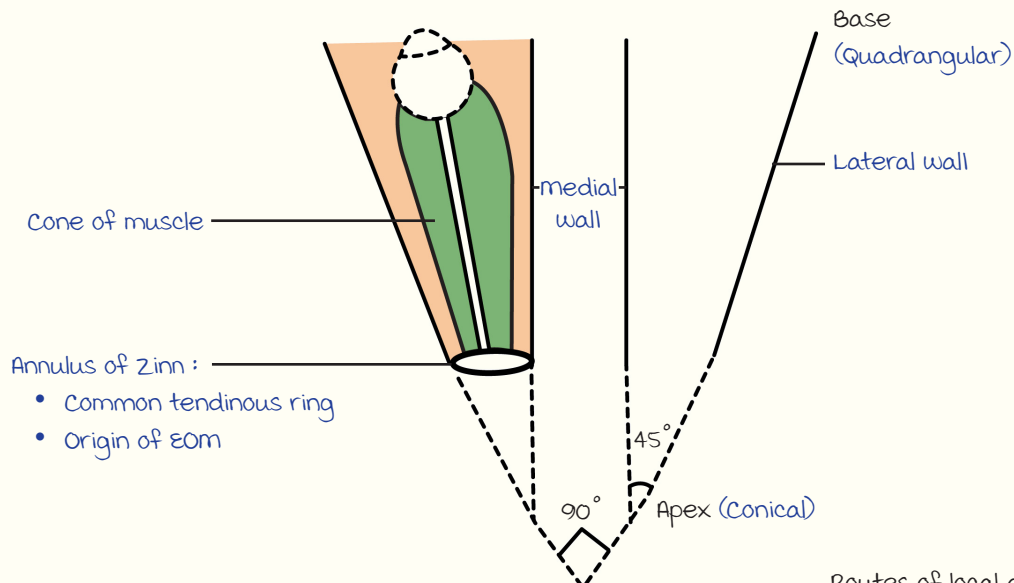
Location : Orbit → 4 walls.

- Thinnest wall : **medial**.
- Weakest wall : **Floor**.
 - m/c orbital fracture : Blow out fracture.



Blow out fracture

Orbital Anatomy :



Routes of local anaesthesia :

- Retrobulbar ■ : Intraconal space
- Peribulbar ■ : Extraconal space
(↓ complications).

Layers of the Eyeball

00:07:20

Outermost :

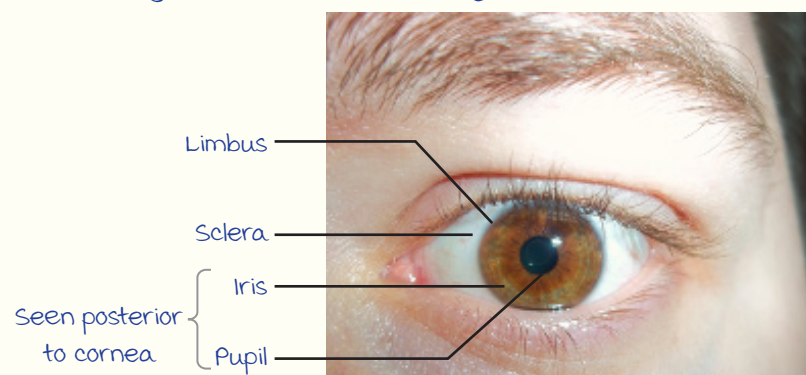
1. Cornea :
 - Transparent.
 - Anterior 1/6th.
 - Convex (Refracts light).
2. Sclera :
 - Opaque (White).
 - Posterior 5/6th.
 - Covered by conjunctiva.
3. Limbus :
 - Corneoscleral junction.
 - Contains stem cells :
 - Specific marker : ABCG2.
 - Universal marker : CD34.

middle : uvea (vascular).

1. Iris :
 - Sphincter pupillae : miosis (Constriction).
 - Dilator pupillae : mydriasis (Dilatation).
2. Ciliary body :
 - Pars plicata (Anterior) :
 - Ciliary projections : Secrete aqueous.
 - Pars plana (Posterior) :
 - Relatively avascular (Point of entry into fundus).
3. Choroid :
 - Posteriormost.
 - ↑vascularity.

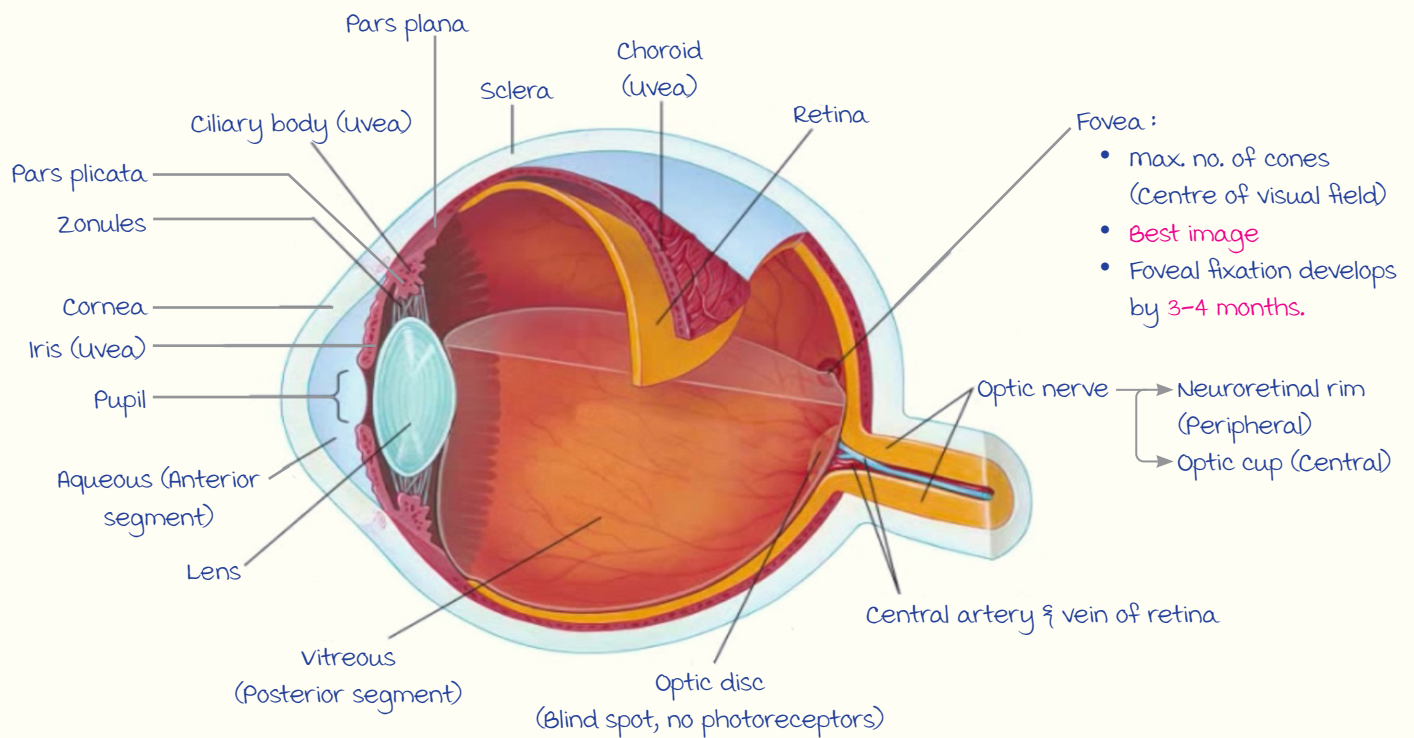
Inner : Retina (Neurosensory).

- Converts sensory impulses into neural signals.



Cross-section of Eyeball :

----- Active space -----



Note : Pars plana gives the site of entry into vitreous.

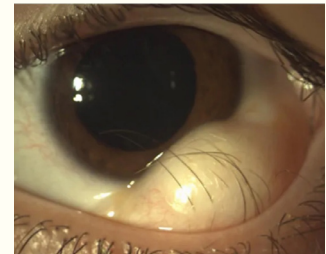
Limbal Pathologies :

1. Limbal dermoid :

- Benign, congenital tumour.
- Choriostomatous tissue ⊕ (Bone, cilia, hair follicles etc).

2. Pterygium :

- Limbal stem cell deficiency.
- Conjunctiva grows over cornea (Normally, conjunctiva only covers the sclera).



Limbal dermoid

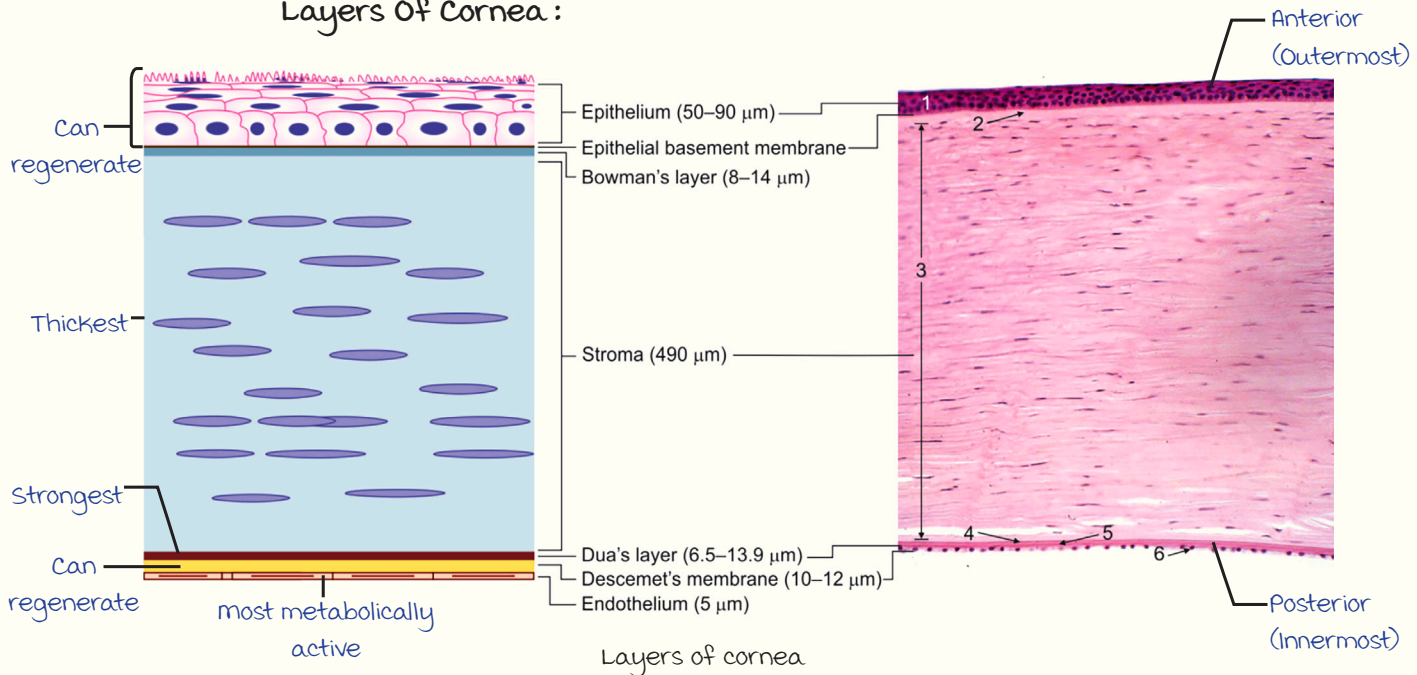
CORNEA AND SCLERA

----- Active space -----

Anatomy Of Cornea

00:01:00

Layers Of Cornea :



1. Epithelium :

- Non-keratinized stratified squamous epithelium.
- Layers :
 - Superficial : Squamous (microvilli ⊕) → Adhesion of tear film).
 - Basal : Columnar (mitosis ⊕) → Regeneration).

2. Bowman's layer :

- False basement membrane (PAS -ve).
- Acellular
(No regeneration → Heals by scar formation → Corneal opacity → LOV).

Corneal opacities :

	Pupillary margin	Iris details	Depth of involvement
Nebular (Faintest)	visible	visible	Bowman's & superficial stroma
macular	visible	Not seen	≤ 1/2 stroma
Leucoma (most opaque)	Not seen	Not seen	≥ 1/2 stroma

Nebular opacity : maximum discomfort (induces irregular astigmatism).

Leucoma : maximum visual loss.

3. Stroma : made of collagen (m/c Type I) & GAGs (m/c Keratan sulphate).

----- Active space -----

4. Dua's layer : Strongest corneal layer.

5. Descemet's membrane (DM) :

- Previously called the strongest layer.
- Regeneration (+).
- Schwalbes line : Peripheral termination of DM.

6. Endothelium :

- metabolism (+).
- maintains corneal transparency.

No. of endothelial cells (Cells/mm ²)	Significance
2400-3000	Normal
<2400	Corneal compensation
<500 (Critical point)	Corneal decompensation → Edema → Hazy cornea

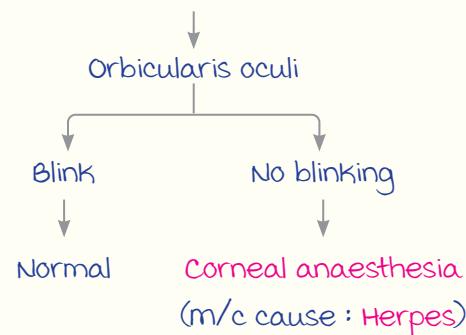
Note : Counted using specular microscopy

Nerve Supply (Sensory) :

TON : Trigeminal → Ophthalmic → Nasociliary

Test for corneal sensations :

Cotton wisp → Touch cornea → CN V (Afferent) → Brain → CN VII (Efferent)



General Properties of Cornea :


Corneal shape : Convex (Converging) } Curvature ∝ Power
 Corneal power : +43D to +44D }
 Corneal colour : Transparent (Appears black)

1. Pachymetry :

- measures corneal thickness (CT).
- Normal CT ~ 540 microns/0.54 mm.

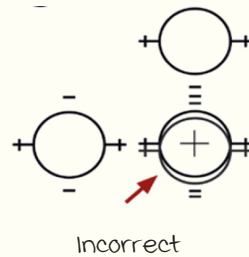
2. Keratometry :

- measures corneal curvature.
- Astigmatism : Vertical curvature \neq Horizontal curvature.

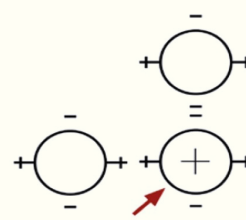


Keratometer

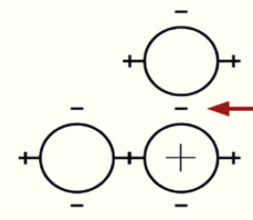
Positioning of
keratometric
mires



Incorrect



Incorrect



Correct

3. Topography :

Examination of corneal surface using Placido disc.



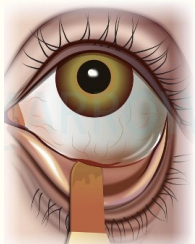
4. Staining :

a. Fluorescein dye :

- Stains areas of broken epithelium (Ulcer base).

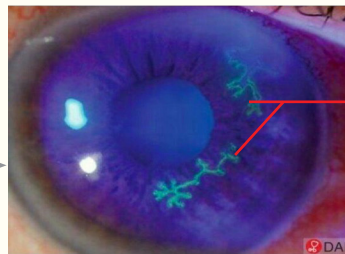
• Other uses :

- Goldmann's applanation tonometry.
- Seidel's test (To locate site of perforation).
- Tear film break up test (To detect dry eyes).



Orange dye used

Viewed under
Cobalt blue filter

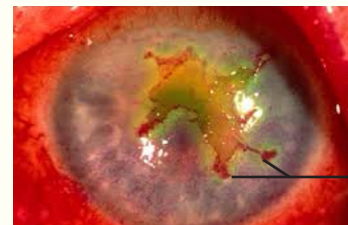


Green fluorescence

Areas of
broken
epithelium

b. Rose Bengal dye :

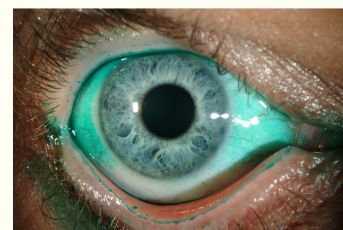
Stains areas of necrotic tissue (Ulcer margins)



Necrotic
tissue (Red)

c. Lissamine green dye :

- Stains both cornea + conjunctiva.
- Used in dry eyes > Corneal ulcer.
- Does not destroy normal tissue (Non-toxic).



Corneal Ulcer

00:26:45

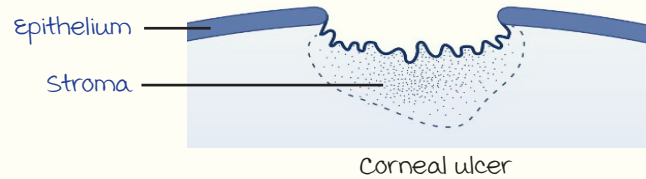
----- Active space -----

Loss of epithelium + Necrosis of underlying tissue

w/o necrosis

Abrasion.

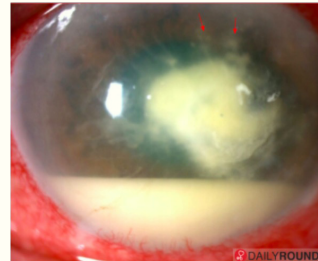
(Regenerates)



BACTERIAL CORNEAL ULCER

Pneumococcus/S. pneumoniae :

- m/c cause (India).
- *Ulcus serpens* : Snake shaped ulcer.
- *Hypopyon* : mobile & sterile collection of pus in anterior chamber.



Hypopyon

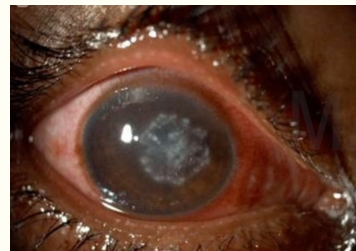Nocardia :

- Seen in traumatic cases.
- Wreath/pin head pattern ulcer

Note :

Pseudomonas :

m/c cause of corneal ulcer in contact lens users.



Wreath/Pin head pattern ulcer

Organisms that can penetrate intact cornea :

mnemonic : High Level CNS

- *Haemophilus aegyptius*
- *Listeria*
- *Corynebacterium diphtheriae*
- *Neisseria gonorrhoeae*
- *Neisseria meningitidis*
- *Shigella*

management :

mnemonic : SS

1. Scrape base of ulcer using blunt edge of 15 no. blade.
2. Gram staining & culture.
3. Start fortified antibiotics.
4. Supportive therapy : Atropine → Cycloplegia relieves pain.
5. Avoid steroids.

----- Active space -----

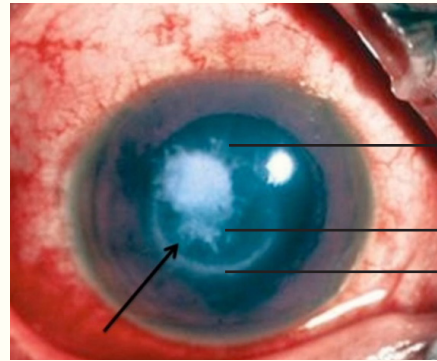
FUNGAL CORNEAL ULCER

- m/c cause : **Aspergillus** (Filamentous, septate).
- H/o : Trauma with **vegetative material**.

Symptoms : mild pain & redness.

Signs :

- Dry ulcer.
- Feathery margins.
- Satellite lesions.
- **Wessley immune ring** (Ag-Ab reaction).
- Hypopyon : **Immobile & unsterile**.



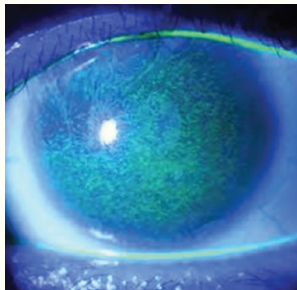
Fungal corneal ulcer

Treatment :

- DOC : **5% Natamycin** eye drops.
- Rest of the management is similar to bacterial corneal ulcers.

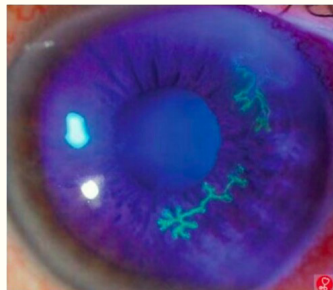HERPETIC KERATITIS

Disease Progression :



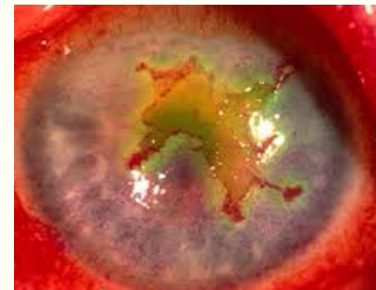
Superficial punctate keratitis

IF
untreated



Dendritic ulcer

IF
untreated



Geographic ulcer

Treatment :

- **3% Acyclovir** eye ointment.
- Steroids **contraindicated**.

Other Lesions d/t Herpes :

- Necrotising stromal keratitis
 - Disciform keratitis/endothelitis
 - metaherpetic keratitis/neutrophic ulcer : **CN V atrophy/palsy** → Corneal anaesthesia.
- Rx : **Topical steroids** (Intact epithelium) + Oral acyclovir

Note :

1. Neuroparalytic ulcer (Not d/t herpes) : **CN VII palsy** → Loss of blinking (Lagophthalmos) → **Exposure keratitis** → Neuroparalytic ulcer.
2. Lagophthalmos seen in Leprosy & Bell's palsy.

ACANTHAMOEBA KERATITIS

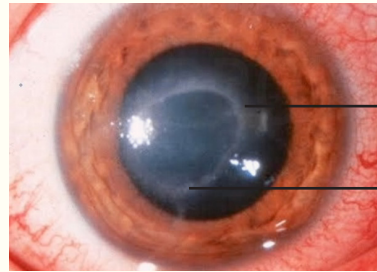
----- Active space -----

Contact lens users + Dirty water (Swimming/cleaning lens with tap water).

Symptoms : Severe pain d/t nerve inflammation. (Radial keratoneuritis)

Signs :

- Radial keratoneuritis.
- Ring abscess.
- Pseudodendrites.



Pseudo dendrites
Ring abscess

Culture :

Non-nutrient agar enriched with E.coli.
(Pseudopods seen)

Treatment :

- PHMB 0.02% (DOC)
 - Chlorhexidine 0.1.%
 - Propamidine
- } Accessible

Corneal Dystrophies

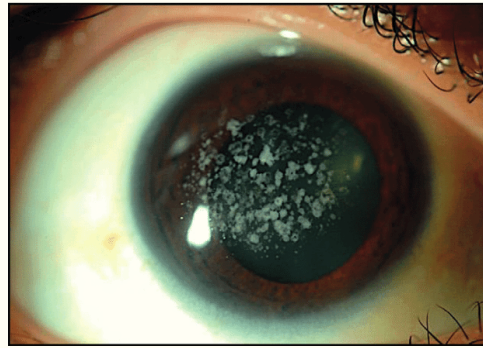
00:51:30

- B/L, non-inflammatory opacifying disorder.
- Autosomal dominant.

Types :

Dystrophy	Site	Features
Cogan's epithelial basement membrane dystrophy	Epithelial (mnemonic : CML)	m/c type
meesman's epithelial dystrophy		Keratin gene mutation
Lisch epithelial dystrophy		Autosomal dominant > X-linked dominant
Reis Buckler's dystrophy	Bowman layer (mnemonic : RST)	Fish net
Schnyder central crystalline dystrophy		Corneal lipid metabolism disorder
Thiel Behnke dystrophy		Honeycomb pattern opacities
Lattice corneal dystrophy	Stromal	Amyloid deposit (Stained by Congo red)
Granular corneal dystrophy		Hyaline deposits (Stained by masson trichrome)
macular corneal dystrophy		Least common, Autosomal Recessive (AR)
Fuch's endothelial dystrophy	Endothelial	Cornea guttata : Wart like excrescences on posterior cornea
Posterior polymorphous corneal dystrophy		AR inheritance, perinatal onset
Congenital hereditary endothelial dystrophy		

----- Active space -----



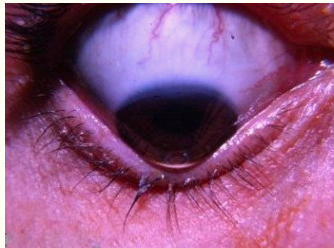Granular corneal dystrophy

Keratoconus

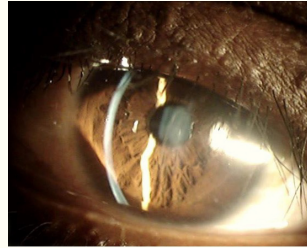00:54:45

Cone-shaped cornea.

Signs :



1. Munson's sign :
V-shaped lower lid



3. Rizzuti's sign :
Light thrown from one side refracts to form an arrowhead shape facing the opposite side.

2. Irregular astigmatism (myopic).
3. Vogt's striae (D/t stretching of cornea).
4. Fleischer's ring : D/t iron deposition.
5. Oil droplet reflex : On ophthalmoscopy.
6. Scissoring reflex : On retinoscopy.

Note :

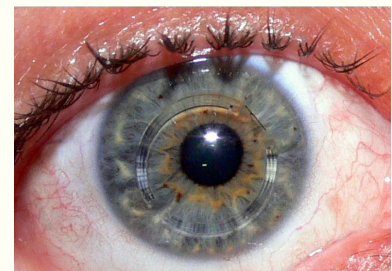
Kayser fleischer ring : D/t Cu deposition in Wilson's disease.

Investigation :

Topography (IOC).

Treatment :

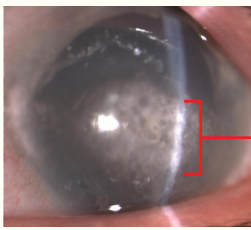
- INTACS's surgery : Intracorneal stromal ring segments.
- Rigid contact lens.
- Keratoplasty : Corneal transplantation (Cadaveric donor).
- Corneal collagen cross linking with riboflavin & UVA radiation (C3R) : Best initial treatment.



INTACS Sx :
Ring stretches the cornea

Note :

Band shaped Keratopathy



Band shaped Ca^{2+} deposition
in Bowman's layer

Treatment : Chelation with EDTA.

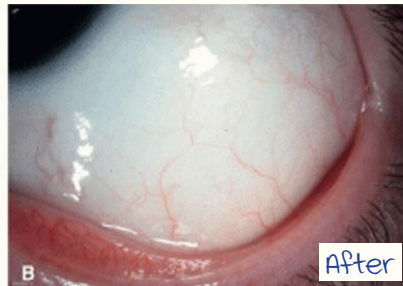
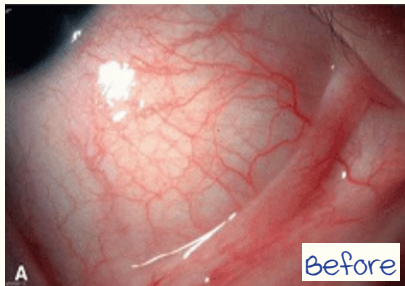
----- Active space -----

Sclera

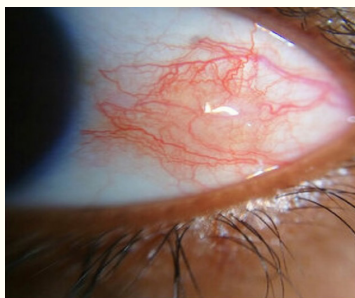00:59:45

Episcleritis vs. Scleritis :

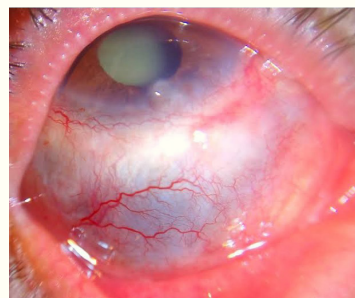	Episcleritis	Scleritis
Inflammation of	Superficial vessels	Deep vessels
Hue	Reddish	Bluish/violaceous
Pain	mild	Deep seated, chronic
Response to phenylephrine (Vasoconstrictor)	Redness disappears (Blanching)	Redness persists (No blanching)



Episcleritis : Phenylephrine test



Nodular episcleritis



Scleritis (Longstanding)
Bluish discoloration

Note :

Scleromalacia perforans :

- Anterior necrotising scleritis without inflammation.
- No redness/pain → Progressive atrophy → Scleral perforation.
- m/c in women with rheumatoid arthritis.

NEURO - OPHTHALMOLOGY

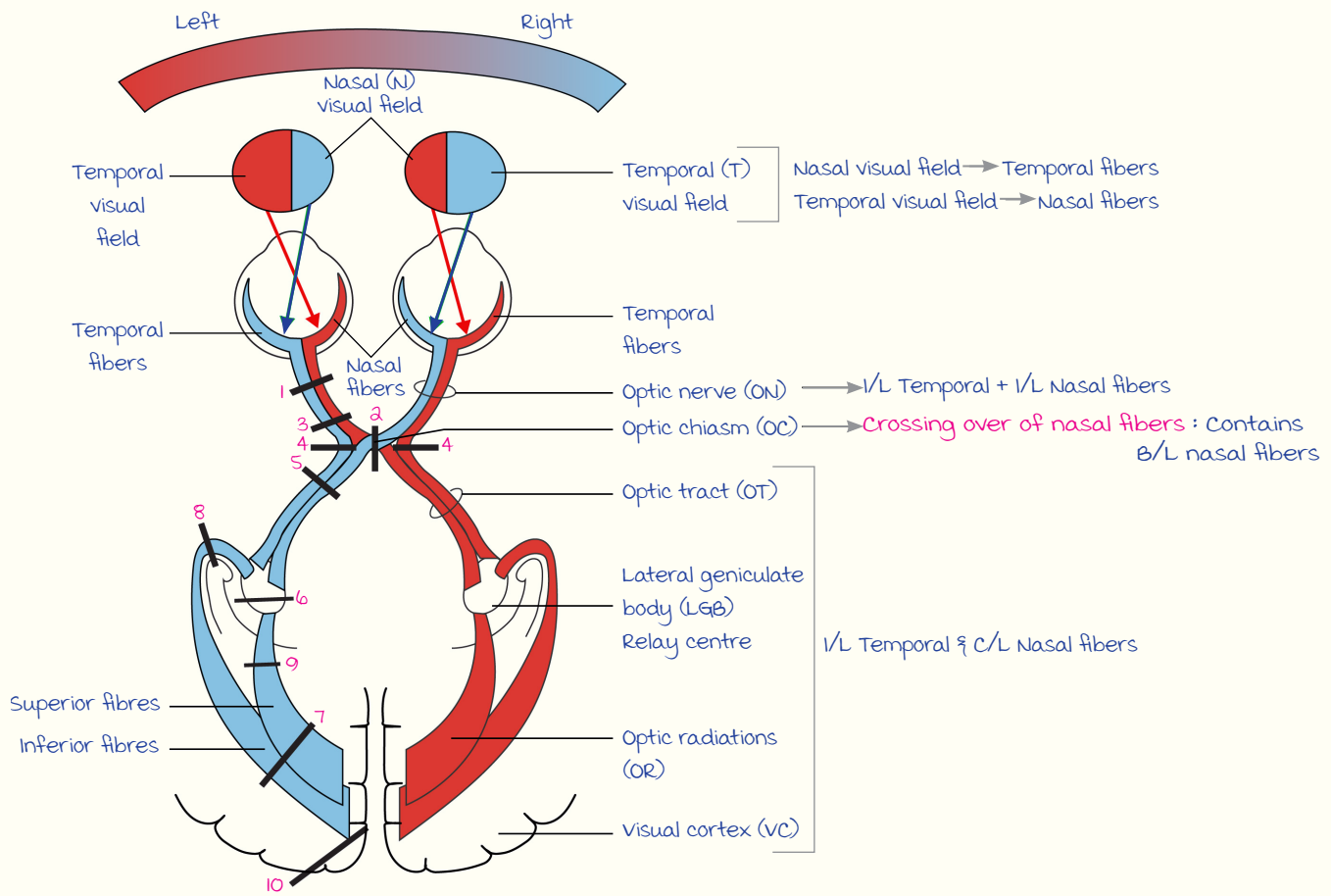
----- Active space -----

Visual Pathway

00:01:29

Retina :

- Covers posterior part of eye till ora serrata.
- Deficient anteriorly.



Note : FOF

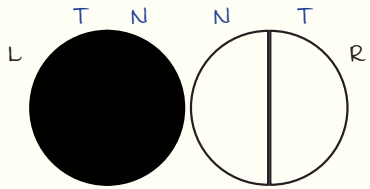
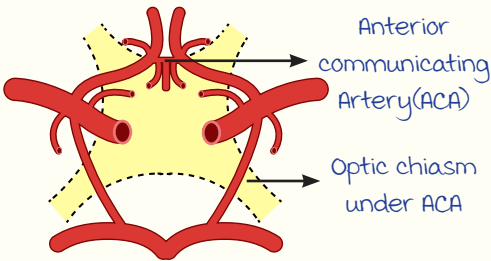
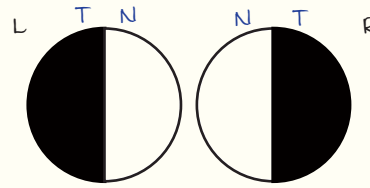
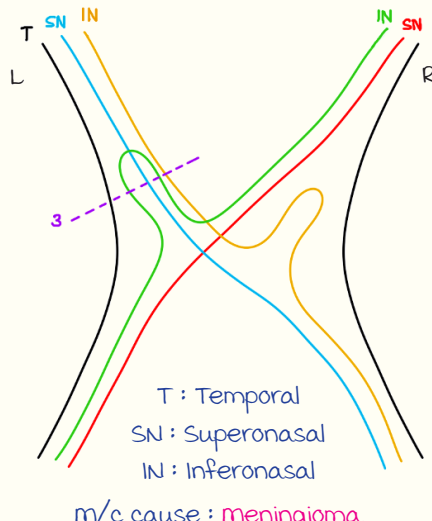
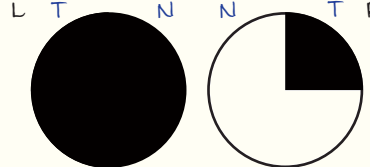

Field loss is opposite to loss of fibres. (Temporal fibres injured → Nasal field lost.)

Visual Field Defects

00:07:10

----- Active space -----

Left sided lesions are described below :

Fibres affected	Visual field defects (VFD)
<p>1. Optic nerve : 1/2 temporal + 1/2 nasal</p>	 <p>1/2 anopia (Blindness)</p>
<p>2. Optic chiasma : 1/2 nasal</p> 	 <p>Bitemporal/Heteronymous Hemianopia</p>
<p>3. Junction of ON & OC (Proximal ON) : Anterior knee of von Willebrand</p>  <p>T : Temporal SN : Superonasal IN : Inferonasal m/c cause : meningioma</p>	 <p>Junctional scotoma</p>
<p>4. Lateral optic chiasma : - 1/2 temporal (Always B/L) - very rare</p>	 <p>Binasal hemianopia</p>

----- Active space -----

Fibres affected	Visual field defects
<p>5. OT 6. LGB 7. OR 10. VC (Rare)</p> <p>→ I/L temporal + C/L nasal</p>	<p>C/L homonymous hemianopia</p>
<p>8. Inferior OR : meyer's loop Inferior I/L temporal + C/L nasal</p> <p>9. Superior OR : Baum's loop Superior I/L temporal + C/L nasal</p> <p>F : Frontal lobe T : Temporal lobe P : Parietal cortex VC : Visual cortex</p>	<p>C/L homonymous superior quadrantanopia, AKA "Pie in the sky." mnemonic : TIPS (Temporal inferior pie in the sky)</p> <p>C/L homonymous Inferior quadrantanopia, AKA "Pie on the floor."</p>
<p>10. Occipital lobe lesion :</p> <p>a. Tip of cortex lesion : macular representation I/L temporal + C/L nasal</p> <p>b. Visual cortex except tip : I/L temporal + C/L nasal except macular representation</p>	<p>C/L homonymous macular defect</p> <p>C/L homonymous hemianopia with macular sparing.</p>

Causes for bitemporal hemianopia : 3PC & AC

----- Active space -----

1. 3rd ventricular glioma → CSF blockage → ventricular dilatation → Optic chiasma compression.
2. Pituitary macroadenoma (>10 mm/1 cm).
3. Craniopharyngioma.
4. Anterior communicating artery aneurysm.
5. Cavernous sinus thrombosis.

Difference b/w lesions at 5, 6, and 7 :

	OT Lesion (5)	LGB Lesion (6)	OR Lesion (7)
Pupil	Abnormal : Wernicke's pupil	Normal	Normal
Optic atrophy	Present bilaterally	Present	Absent (Optic radiations are post ganglionic : 4 th order)
Congruity	Incongruous	Incongruous	Congruous

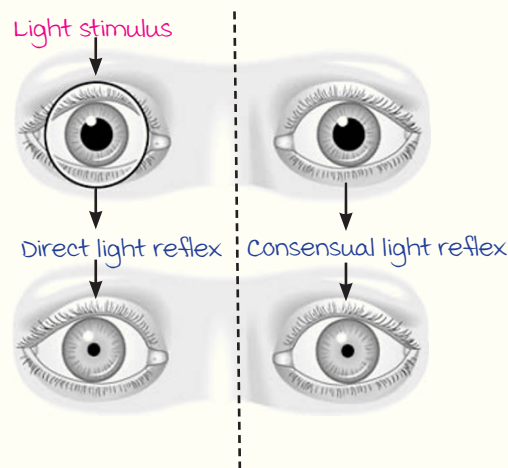
Pupillary Reflex

00:34:04

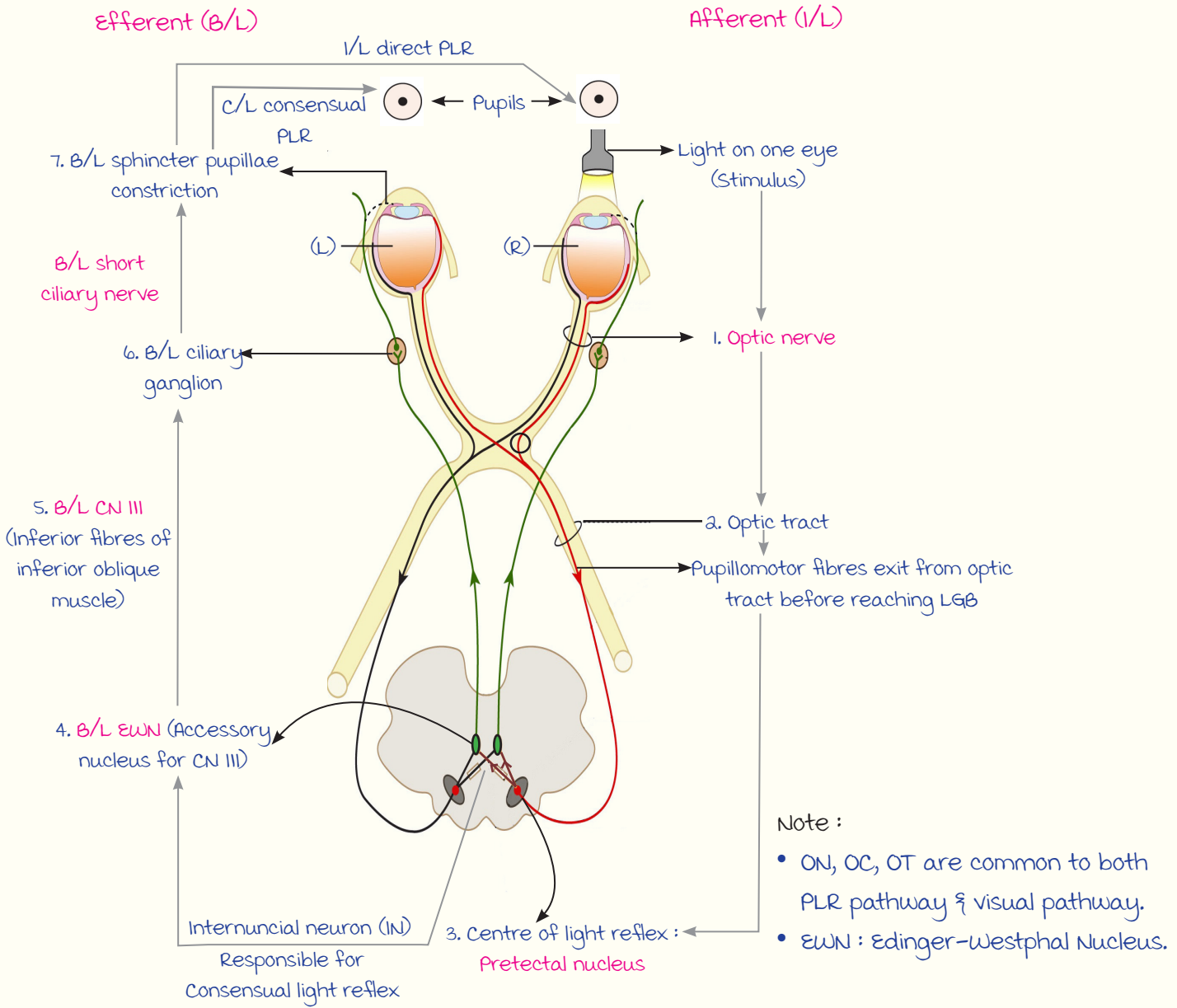
Pupillary Light Reflex :

Light → Pupil → Constrict/dilate

Types : Direct and consensual.

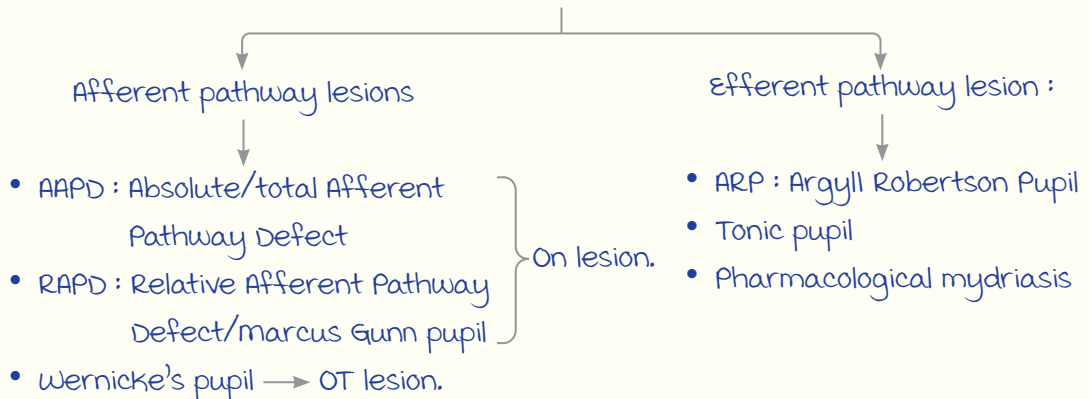


----- Active space ----- Pupillary Pathway :



Lesions of Pupillary Light Reflex

00:39:14



Afferent Pathway Lesions :

----- Active space -----

	AAPD	RAPD
Findings	<p>Light stimulus on (N) eye : B/L pupils constrict</p> <p>Light stimulus on lesion side : B/L pupils do not constrict</p>	<p>Light stimulus on (N) eye : B/L pupils constrict</p> <p>Light stimulus on lesion side : B/L pupils dilate</p> <p>Swinging flashlight test → Partial on lesion ↓ Paradoxical dilatation ← Nerve fatigue of pupils</p>
Pupils size	Isocoria : Both pupils equal in size	

Efferent Pathway Lesion :

ARP : mnemonic → ARP-PRA

- Accommodation Reflex Present Pupillary Reflex Absent.
- Cause : Neurosyphilis.

	Tonic/Adie's Pupil	Pharmacological mydriasis
Cause	Lesion at ciliary ganglion/short ciliary nerve	Drugs : Atropine
Light reflex	<p>Eg : Lesion/mydriatic application at right eye</p> <p>Light on normal side</p> <p>Light on lesion side</p> <p>1/L pupil does not constrict (AKA tonic pupil)</p>	
Pupil size	Anisocoria : Both pupils unequal in size	

----- Active space -----

	Tonic/Adie's Pupil	Pharmacological mydriasis
Accommodation reflex	Normal	Absent MOA: Cycloplegic action ↓ Relaxation of ciliary muscle ↓ Loss of accommodation.
Diluted Pilocarpine (0.125%)	Constricts d/t denervation hypersensitivity MOA: Sphincter pupillae denervated ↓ Over-expression of receptors ↓ Hyperreactive to stimuli.	Does not constrict (Even with 1% pilocarpine)

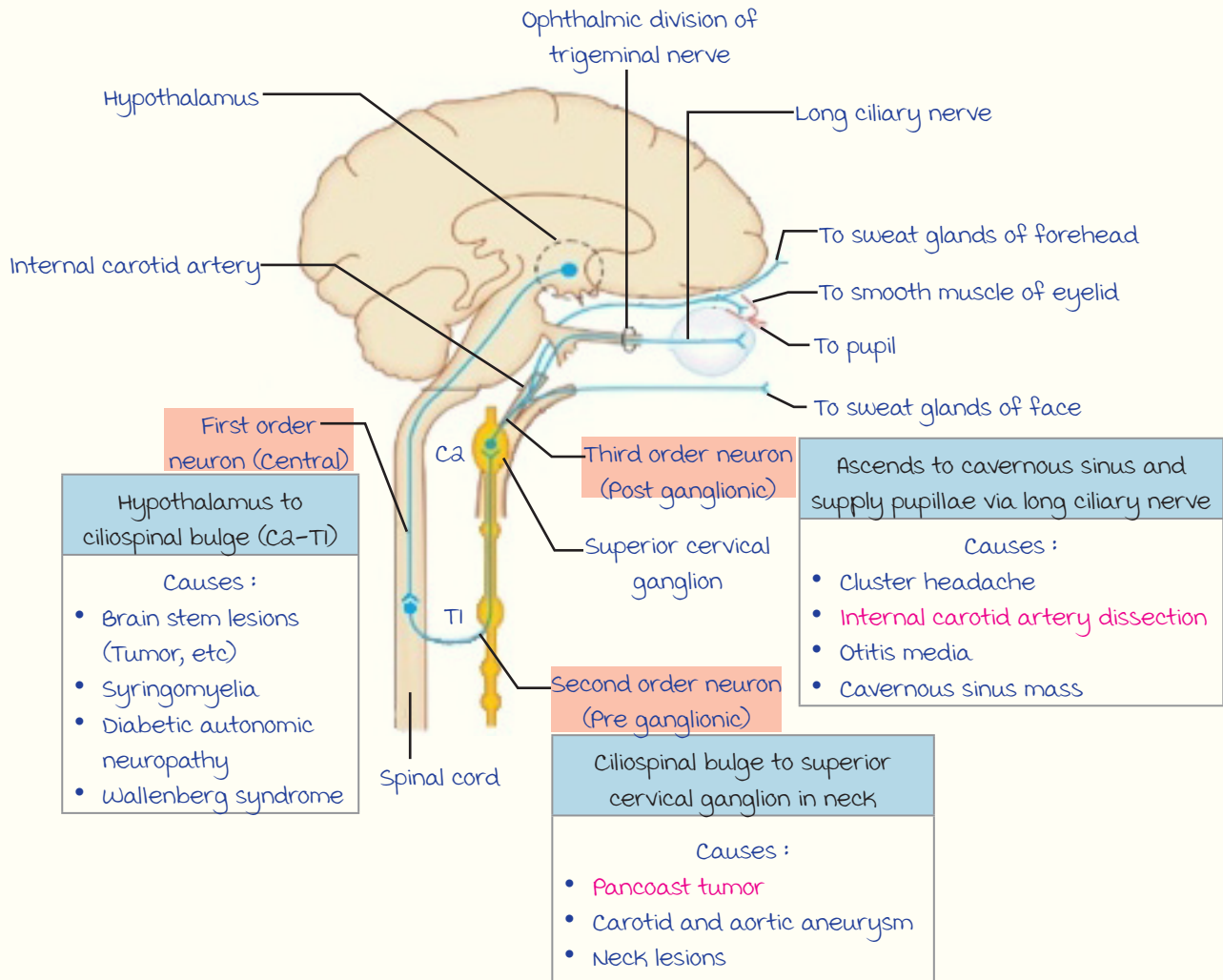
Muscles of Iris

00:51:36

	Sphincter pupillae	Dilator pupillae
Function	miosis (constriction of pupil)	mydriasis (dilatation of pupil)
Autonomic Nerve Supply	Parasympathetic control (Inhibitory) ↓ via ↓ Oculomotor nerve (CN III) ↓ Inferior branch (To inferior oblique muscle) ↓ Short ciliary nerve (Post ganglion)	Sympathetic control (Excitatory) ↓ via ↓ Hypothalamus ↓ 1° neuron ↓ Ciliospinal bulge (C8-T1) Crosses over lung parenchyma ↓ 2° neuron ↓ Superior cervical ganglion Through cavernous sinus ↓ Long ciliary nerve
Final nerve supply		Lesion at any point ↓ Oculosympathetic palsy.

Course and Lesions of Sympathetic Supply to the Iris :

----- Active space -----



Horner's Syndrome/Oculosympathetic Palsy

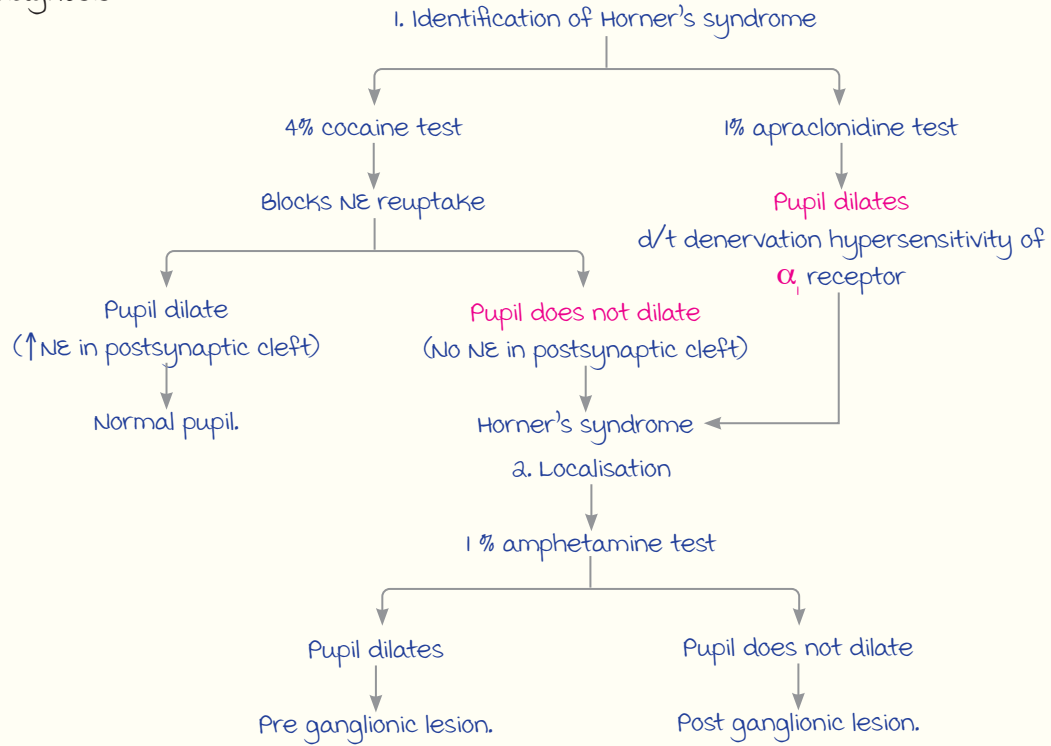
00:53:41

Paralysis of sympathetic pathway of dilator pupillae.

Clinical features : (mnemonic : **HIMAPLE**)


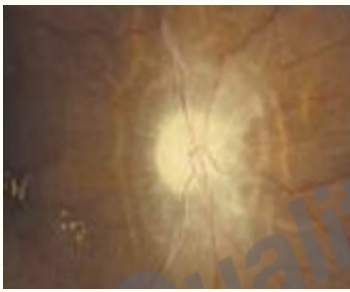
- **H**eterochromia iridis : Hypochromic affected eye (Only in congenital cases).
- **I**nferior eyelid elevation.
- **M**iosis : Paralysis of dilator pupillae → unopposed sphincter pupillae.
- **A**nhydrosis : I/L absence of sweating.
- **P**tosis : Drooping of upper eyelid d/t **muller's muscle paralysis**.
- **L**oss of cilio-spinal reflex.
- **E**nophthalmos (Sunken eyes).

----- Active space ----- Diagnosis :



Optic Atrophy

00:59:33

	Primary (1°)	Secondary (2°)	Consecutive
Definition	Optic atrophy without antecedent optic disc swelling	Optic atrophy after optic disc swelling	Optic atrophy due to disease of inner retina and its blood supply
Disc appearance	Chalky white , well defined margins	Dirty gray-white , ill-defined margins	Waxy pallor of disc
Optic cup	 Chalky white	 Ill defined margins of OD	-
Causes	<ul style="list-style-type: none"> • Optic neuritis • Tumors • Trauma • Hereditary : LEBER's disease (mitochondrial inheritance) • Toxic : Ethambutol 	<ul style="list-style-type: none"> • Papilledema • Papillitis 	Retinal diseases : <ul style="list-style-type: none"> • Retinitis seen • CRAO/CRVO • Healed vasculitis • Panretinal photocoagulation • Retinitis pigmentosa

Optic Neuritis

01:02:50

----- Active space -----

Inflammation of optic nerve.

Cause : **multiple Sclerosis** (m/c).

Clinical features :

mnemonic : **a CUP mar.**

- **C**entral scotoma.
- **C**olor blindness of red & green.
- **u/L** loss of vision.
- **u**hthoff sign : Worsening of symptoms on ↑ body temperature (Eg : Exercise).
- **P**ulfrich sign : Tachokinetic dissociation.
- **P**ain in eye on ocular movements.
- **m**arcus Gunn pupil (RAPD).

Treatment :

- Steroids : Anti-inflammatory for Rx of multiple sclerosis → IV f/b oral.
- Interferons

Papilledema

01:04:52

Signs :

- Blurring of disc margins : **earliest.**
- **Normal vision.**
- Amaurosis fugax : **Transient** loss of vision.

↑ ICP



Temporary block in conduction of impulses



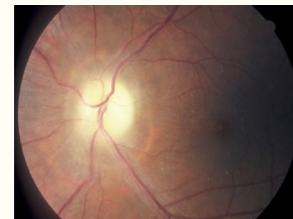Transient blindness

- visual field defects : enlargement of blind spot.
- Paton's lines : Retinochoroidal folds around OD d/t fluid accumulation.

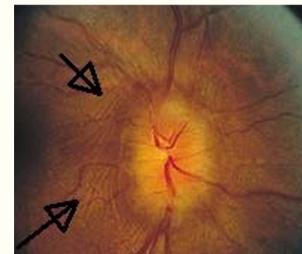
Treatment : Control ICP.

myelinated Nerve Fibres :

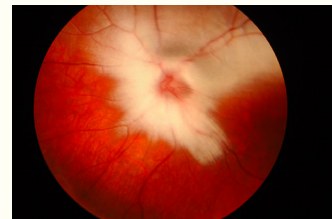- myelination of OD & nerve fibres of retina.
- **No loss of vision.**
- myelination : ↑ Speed of conduction.



Edematous OD :
d/t ↑ ICP



Paton's lines



myelinated nerve fibres

Colour Blindness

01:09:10

1° colors :

- **Red** : Protan.
- **Green** : Deutan.
- **Blue** : Tritan.

----- Active space -----

Etiology :

a. Acquired :

Colors affected	Etiology
Blue-yellow	<ul style="list-style-type: none"> Retinal diseases : <ul style="list-style-type: none"> - CSR - macular edema Primary Open Angle Glaucoma (POAG)
Red-green	Optic nerve lesions : <ul style="list-style-type: none"> Optic neuritis LHON
Blue	Old age

b. Congenital :

X-linked recessive (m > F)



Females are carriers.

Types :

	Dyschromatopsia (Defective)		Achromatopsia (Absent)	
	Dichromatic	Trichromatic anomalous	Rod monochromat	Cone monochromat
Features	<ul style="list-style-type: none"> Perception of 2 colors Blindness for 1 color (Anopia) 	<ul style="list-style-type: none"> Perception of all 3 colors (+) Perception is defective (Anomalous) 	Only rod (+) ↓ Total color blind (Black & white vision)	One type of cone (+) ↓ 1 cone perception
Clinical conditions	<ul style="list-style-type: none"> Protanopia Deuteranopia Tritanopia 	<ul style="list-style-type: none"> Protanomaly Deuteranomaly Tritanomaly 	Hemeralopia (Day blindness)	-

Tests :

	Ishihara chart	Hardy Rand Ritter
Chart		
Features	<ul style="list-style-type: none"> m/c used Disadv. : Cannot detect tritan defects 	used to test pediatric age group
	Farnsworth munsell 100 hue test	Farnsworth munsell 15 hue test
Chart		
Features	most sensitive	Differentiates between congenital & acquired

SQUINT

----- Active space -----

Extraocular Muscles (EOM)

00:01:45

6 EOMs act on eyeball & 1 EOM acts on eyelid (Levator palpebrae superioris).

muscles Acting on the Eyeball :

Action only in 1° gaze :

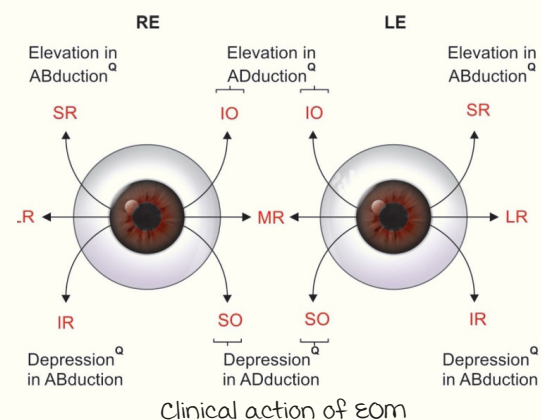
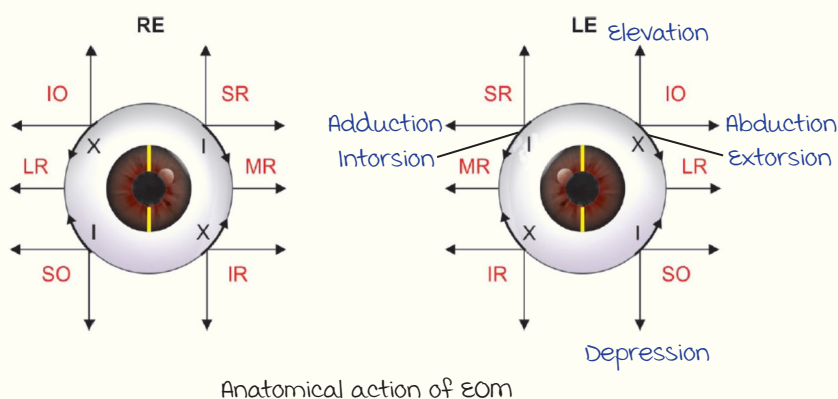
- medial Rectus (MR) : Adduction.
- Lateral Rectus (LR) : Abduction.

Action in 1°, 2° & 3° gaze : (Cyclical action)

muscle	Actions		
	1° (Predominates in abduction)	2° (Predominates in adduction)	3°
Superior Rectus (SR)	Elevation	Intorsion	Adduction
Inferior Rectus (IR)	Depression	Extorsion	
Superior Oblique (SO)	Intorsion	Depression	Abduction
Inferior Oblique (IO)	Extorsion	Elevation	

Nerve supply :

- LR6 : Lateral rectus supplied by Abducent N. (CN 6)
- SO4 : Superior oblique is supplied by Trochlear N. (CN 4)
- Others : CN 3

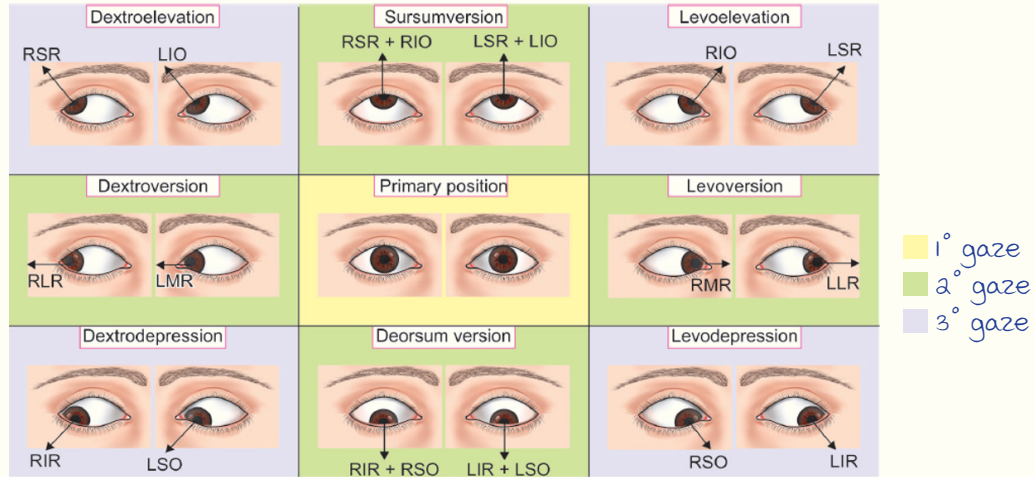


Note : Superior oblique function can be confirmed by asking the pt. to look at the tip of their nose.

----- Active space -----

Terminology related to EOM :

Terminology	Action of the muscles	Examples
Antagonist	Opposite action in same eye	Rt. LR & Rt. MR
Agonists	Same action in same eye	Rt. SR & Rt. IO
Yoke muscles/ Contralateral synergists	One muscle from each eye; helps to look in the same direction. (Version movement)	Rt. MR & Lt. LR



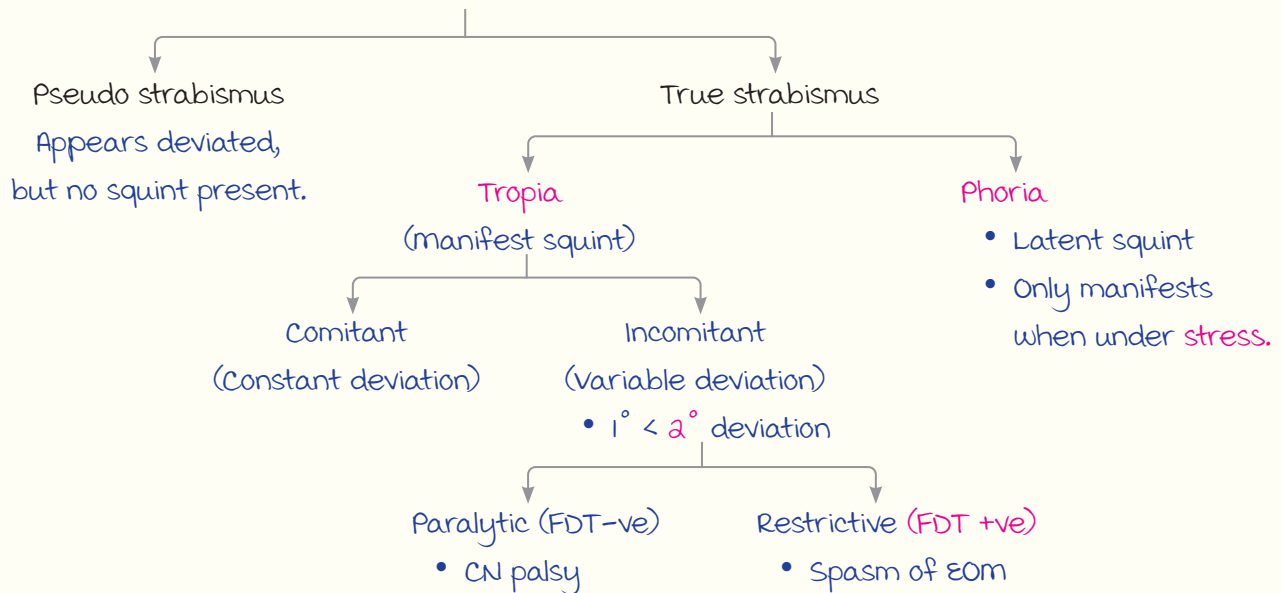
Yoke muscles in different gazes

mechanisms of binocular vision :

- Hering's law : Equal innervation to yoke muscles.
- Sherrington's law : Reciprocal inhibition to antagonist (Relaxes).
- A defect in these mechanisms lead to squint.

Types Of Squint

00:14:03

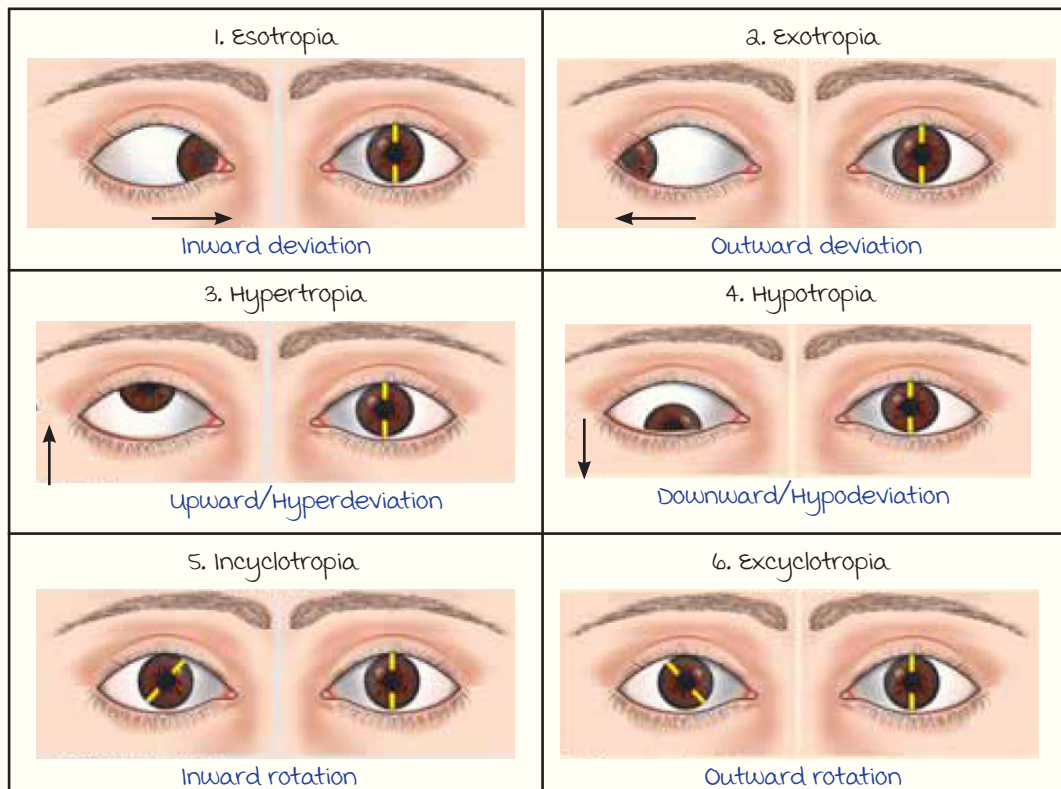


Forced Duction Test (FDT) is diagnostic only for restrictive squint.

Directions of deviation :

All deviations of the right eye in below examples.

----- Active space -----



Note :

Incyclotropia and excyclotropia are clinically not visible. → Dx : Double maddox rod test.

Investigations

00:19:06

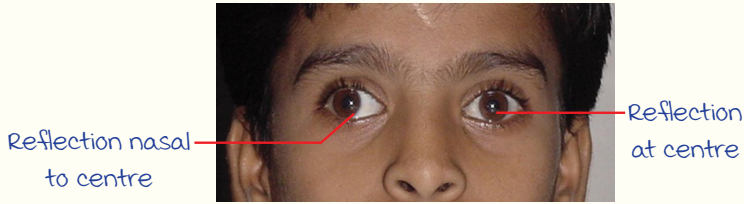1. Ocular movement examination : In all directions of gaze.
2. Calculate refractory error : To rule out hypermetropia (Esotropia seen in Hypermetropia).
3. measure fusional vergence :
 - Extra power needed to prevent esophoria.
 - Dx : RAF ruler.
4. measure ocular deviation :
 - a. Hirschberg's test.
 - b. Cover-uncover test.
 - c. maddox rod.
 - d. PBCT (Prism Bar Cover Test).
5. measurement of diplopia :
 - e. Hess chart (m/c)
 - f. Lee's screen.
6. Tests for sensory anomalies :
 - g. worth 4 dot test (m/c).
 - h. Bagolini striated glass.

----- Active space ----- **MEASUREMENT OF OCULAR DEVIATION**

1. Hirschberg's Test :

Interpretation :

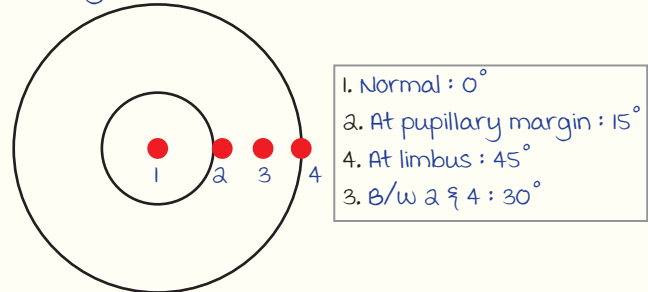
a. Direction of deviation



DOOR : Deviation
Opposite Of Reflection

Temporal deviation.
(AKA : Exotropia)

b. Degree of deviation :



Position of corneal reflection

Note :

- 1 prism dioptre = 0.5 degree.
- 1 mm deviation = 7° of squint.

2. Cover & Uncover Test :

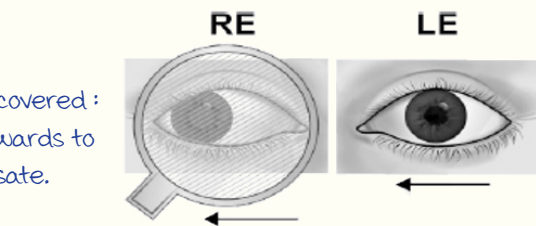
- Cover test → Tropia.
- Uncover test → Phoria.

Doom : Deviation Opposite Of movement.

a. Cover test :

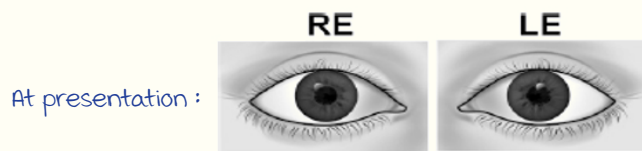

Normal eye covered :
LE moves inwards to compensate.

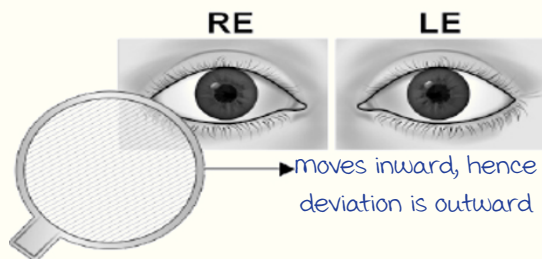
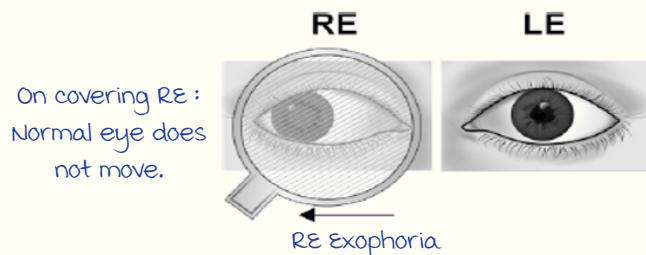


Normal eye uncovered :
LE returns to its original position.

b. Uncover test:



On covering RE :
Normal eye does not move.

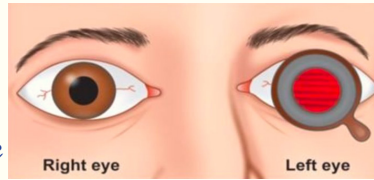


RE returns to initial position on uncovering

3. Maddox Rod Test :

Uses :

- Diagnose **phoria** at **far** fixation.
- macular function test.
- Cyclotropia measurement with double maddox rod test.




maddox rod test



----- Active space -----

4. Prism Bar Cover Test :

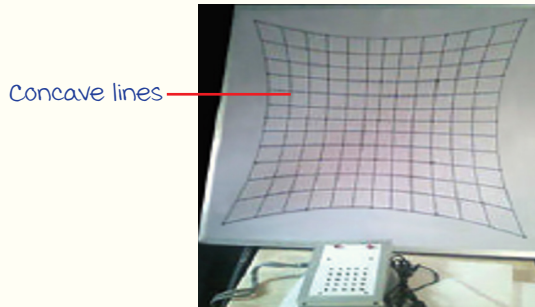
- **most accurate test** to measure degree of tropia.
- **Base of prism** : Placed **opposite to direction of deviation**.



Prism bar

MEASUREMENT OF DIPLOPIA

5. Hess Chart :





Note :
Amsler's grid has straight lines, not concave.

6. Worth 4 Dot Test :

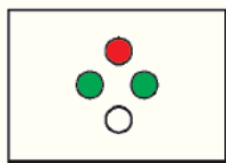Equipment :

4 dots :

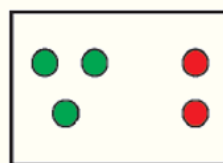
- 1 Red
- 2 Green
- 1 white



Interpretation :



Normal binocular single vision :
Harmonious ARC



Non-harmonious
ARC (Diplopia)



RE suppression



LE suppression

Note : ARC → Anomalous Retinal Correspondence.

----- Active space -----

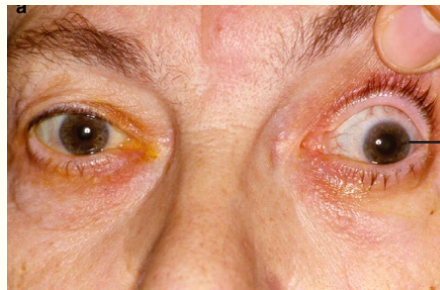Paralytic Squint

00:35:49

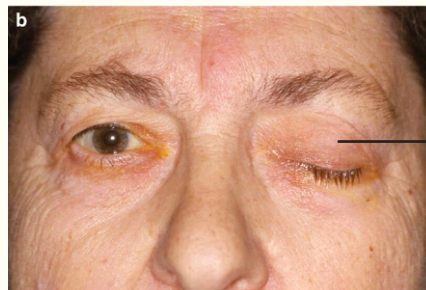- C/f : opposite direction
 - Head tilt : Same direction
- } To action of paralysed EOM

	muscles	Action	Palsy	Other C/F	mx
3 rd CN Palsy	LPS	Elevation of lid	Ptosis	Crossed diplopia	wait and watch. (CN III regenerates as it is covered by neurilemma)
	SR, IO	Elevation	Hypotropia		
	MR	Adduction	Exotropia		
	Sphincter pupillae	miosis	mydriasis		
	Ciliary muscle	Accomodation	Loss of accomodation		
4 th CN Palsy	Superior oblique	Intorsion (1°)	Encyclotropia	<ul style="list-style-type: none"> • Chin depression. • C/L Head tilt. 	Confirmation of Dx : Park's 3 step test.
		Depression (2°)	Hypertropia		
		Depression in adduction	↑Hypertropia on adduction/opposite gaze		
6 th CN Palsy	Lateral rectus	Abduction	Esotropia	<ul style="list-style-type: none"> • uncrossed diplopia. • I/L face turn. 	-

3rd nerve palsy :



Down & out pupil



Ptosis

4th nerve palsy : Park's 3-step test.



LE hypertropia

↑↑Hypertropia (Worse on opposite gazes)



← Right gaze

Left gaze →

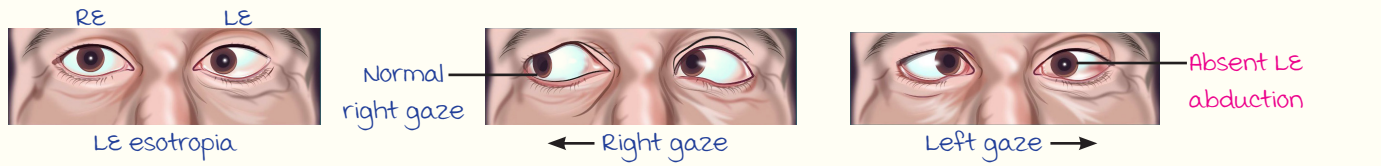Improved hypertropia (Better on opposite tilt)



← Right tilt

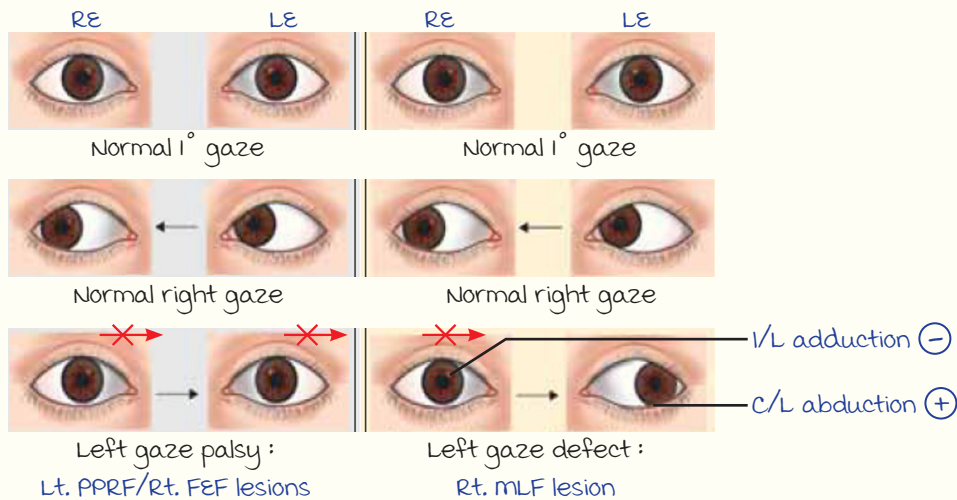
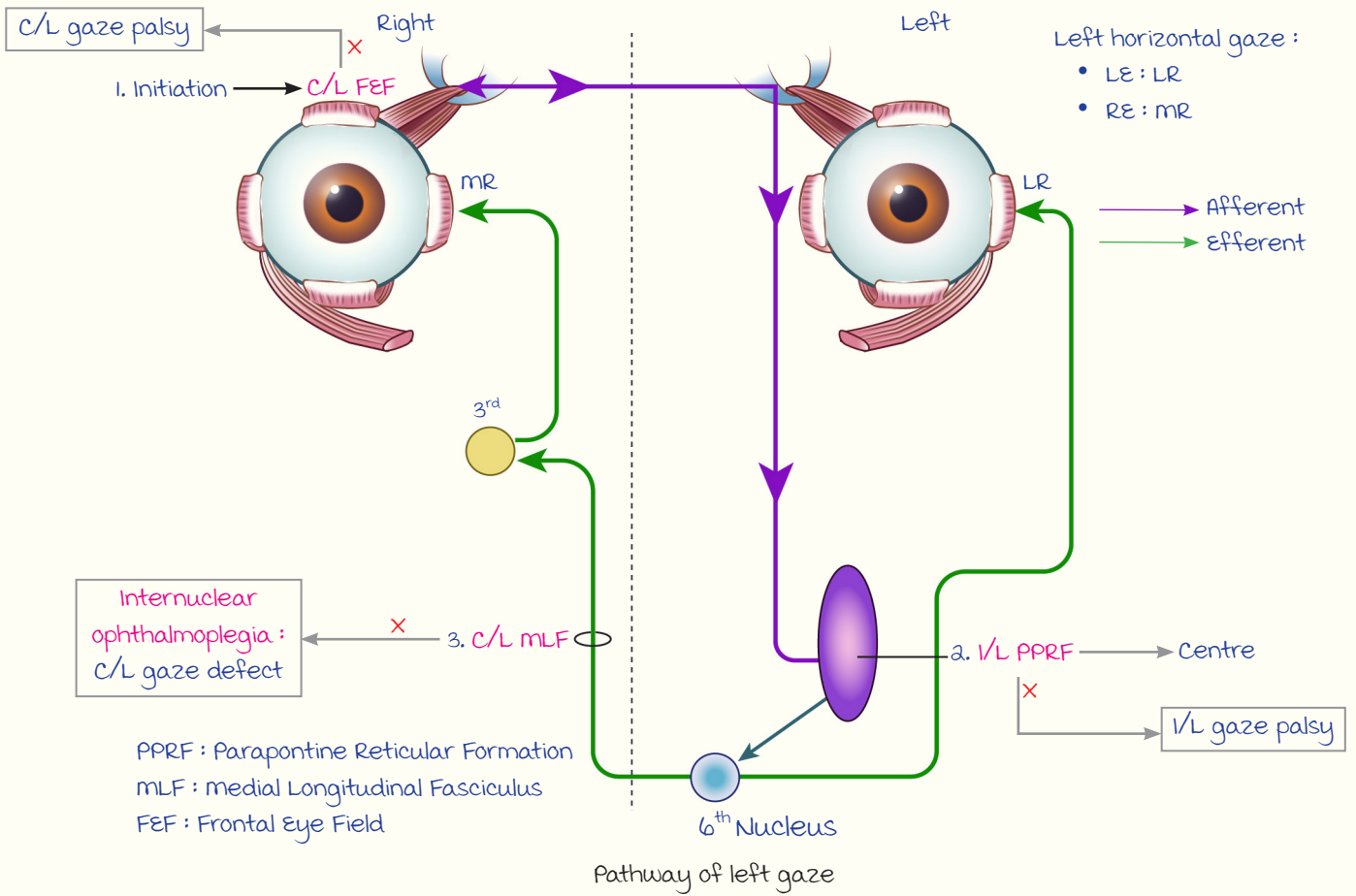
Left tilt →

6th nerve palsy :



Horizontal Gaze (Left Eye)

00:46:18



----- Active space -----

Restrictive Squint

00:52:30

Duane's retraction syndrome :

	Limitation of movements	Palpebral fissure closure (+) Retraction of globe
Type 1	Abduction	Adduction
Type 2	Adduction	
Type 3	Abduction + adduction	

Dx : Forced duction test.

Concomitant Squint

00:53:49

Esotropia/Crossed-eyes :

m/c presentation of concomitant squint.

1. Accomodative : (Role of accomodation (+))

	Refractive	Non-refractive
Cause	Hypermetropia (SO HYPER)	D/t high accomodative convergence/accomodation ratio
Esotropia	Distant > Near	Near > Distant
Rx	Convex spectacles	Bifocal spectacles miotics : Echothiophate

2. Non-accomodative : (Role of accomodation (-))

- AKA essential infantile esotropia.
- 4-6 months of age.
- moA : Large angle squint ($>15^\circ$) \rightarrow 2 eyes focus on different objects

↓
Suppression of deviated eye

↓
Amblyopia (Lazy eye) of deviated eye :
Loss of vision without organic cause.

- No treatment.
- Prevention : **Occlusion therapy** (until 6 yrs of age)

↓
Patch normal eye for 'x' days
(x = Age of child)

↓ F/b

Patch deviated eye for 1 day.

Myasthenia Gravis

01:00:07

----- Active space -----

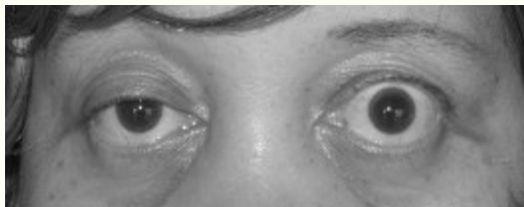Defective function of EOM.

Clinical Features :

- Ptosis :
 - B/L
 - **worsens** as day progresses (D/t ↓ ACh → Fatigue)
- Diplopia
- **Cogan lid twitch sign** : upper eyelid shoots up on switching from downward gaze to upward gaze.

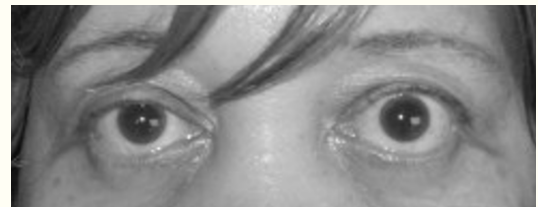Diagnosis :

Tensilon test : **Definitive test.**



Rt. Ptosis

Inj Edrophonium



Improvement of ptosis

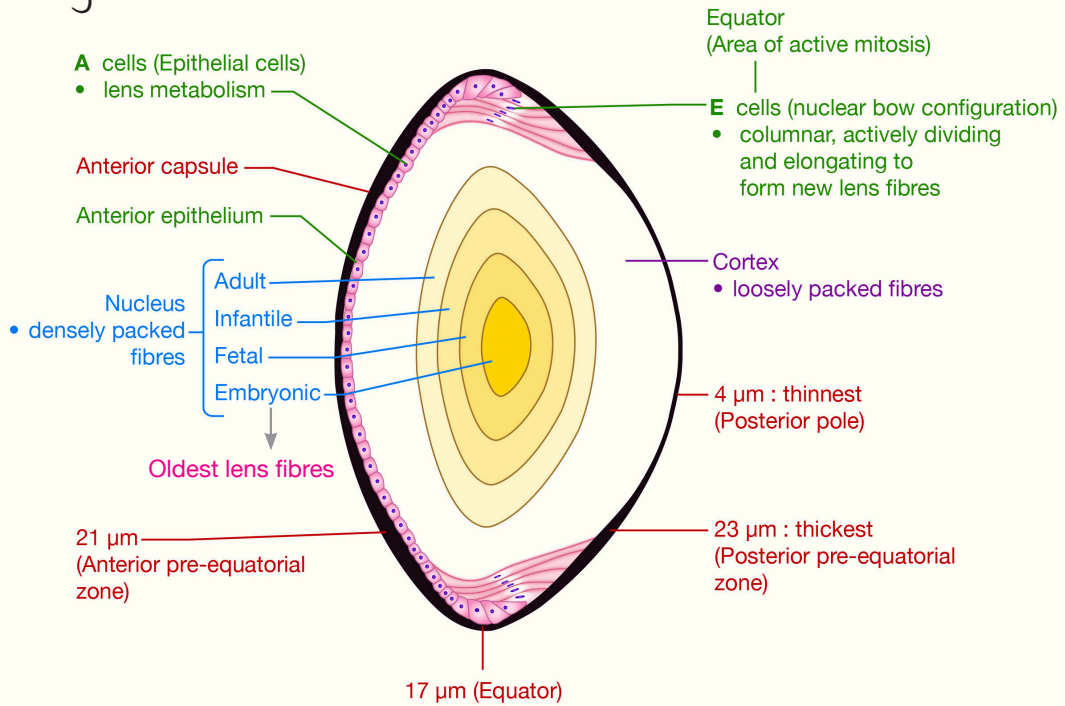
LENS

----- Active space -----

Lens Anatomy & Classification of Cataract

00:01:19

Anatomy :

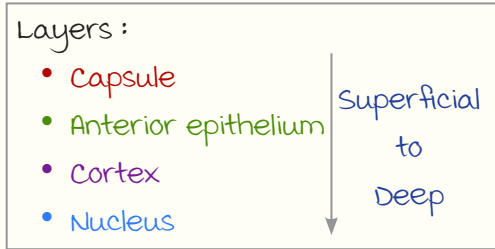


Shape : Biconvex.

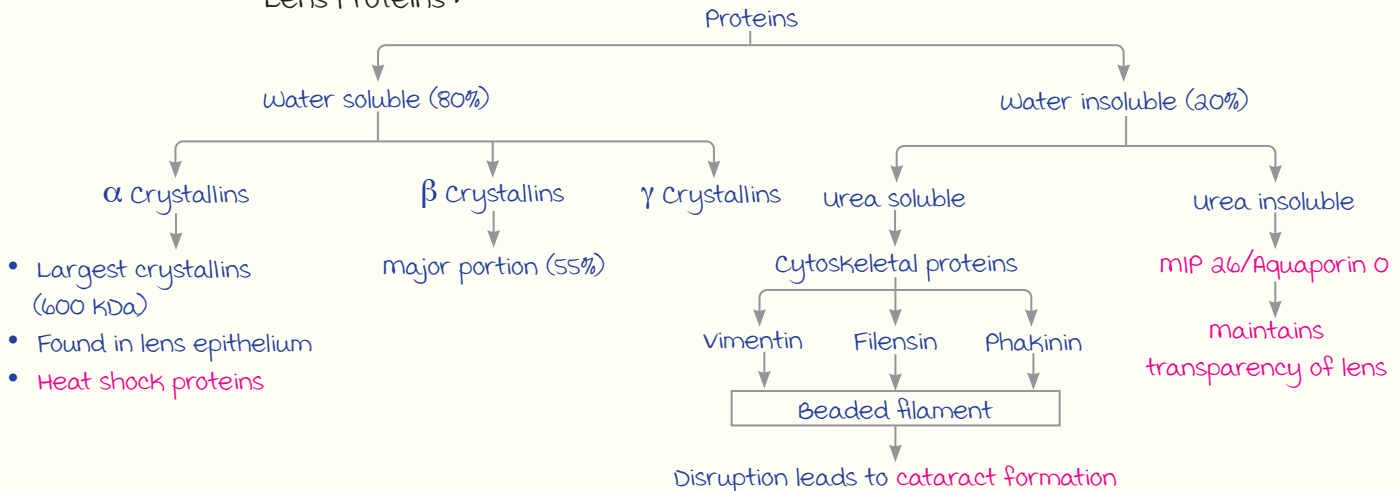
Power : $\oplus 16D$ to $\oplus 19D$.

Colour : Transparent.

Embryological development : Starts on Day 27.



Lens Proteins :



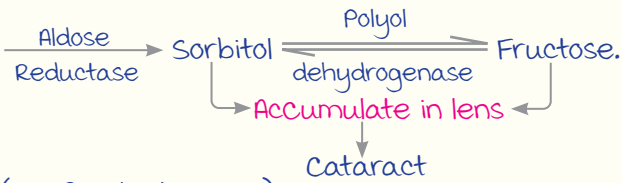
Lens metabolism :

- Lens is avascular.
- Diffusion of glucose occurs via → Aqueous (90%); vitreous (10%).

----- Active space -----

metabolic Pathways :

- Anaerobic glycolysis (>80%).
- kreb's cycle & HMP shunt (~ 15%).
- Sorbitol pathway (<5%) : Glucose

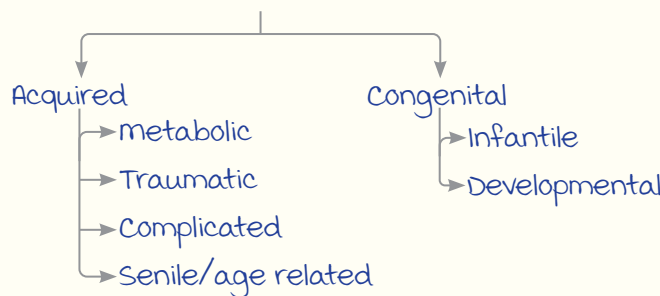


- Normally inactive.
- Activated by hyperglycemia (DM & galactosemia).

Cataract :

- Gradual & painless loss of vision.
- m/c cause of blindness in India.

Classification :

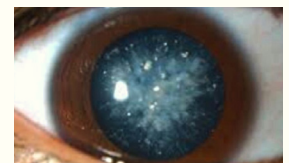

Metabolic Cataract

00:11:37

1. Parathyroid tetany :

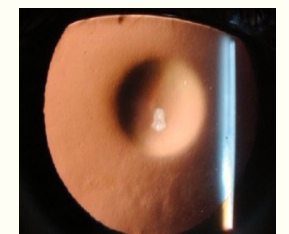
Hypocalcemia → Children : Lamellar cataract.
 → Adults : Anterior & posterior subcapsular cataract.



Snowflake cataract

2. Snowflake cataract :

DM (Type 1 > Type 2) → Carbamylation of crystallins → Cortical cataract.



Oil droplet cataract

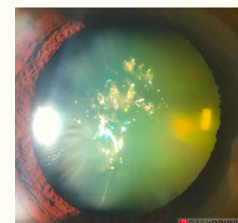
3. Oil droplet cataract :

- Galactosemia → Accumulation of metabolite & substrate → Posterior subcapsular cataract.
- Only reversible cataract.

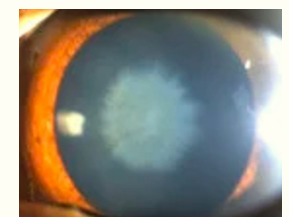
4. Sunflower cataract : D/t Wilson's disease.

5. Christmas tree cataract :

myotonic dystrophy → Posterior subcapsular cataract.

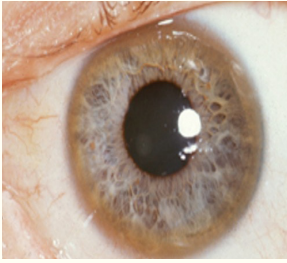


Christmas tree cataract



Sunflower cataract

----- Active space ----- Note :



Kayser Fleischer ring

1. Kayser Fleischer ring : A/w Wilson's disease
 - Golden-brown Cu^{2+} deposition in the Descemet's membrane near the limbus.
 - Progression : Superior \rightarrow Inferior \rightarrow Lateral \rightarrow Circumferential.
 - All cases with neurological manifestation and 50% cases with only hepatic manifestation.
2. Fleischer's ring : A/w keratoconus.
3. Pseudo-Fleischer's ring : A/w hypermetropia.

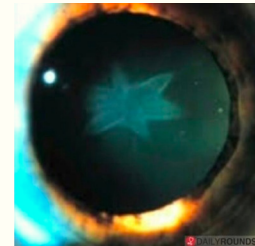
Traumatic Cataract

00:18:38

Noxious stimulus	effect	Cataract
IR rays	True exfoliation of lens capsule	Glassblower's cataract
Lightning/Electric shock	Anterior capsular opacities	Unnamed

BLUNT TRAUMA

Contusion injury \rightarrow Posterior subcapsular cataract.
(Tennis ball/Fist injury) (Rosette shaped cataract)



Rosette shaped cataract

Signs :

1. Hyphema (m/c) :

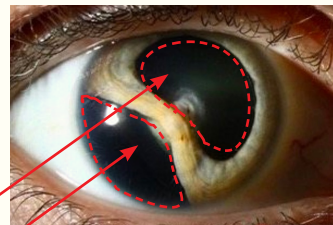
Bleeding from major arterial circle of iris \rightarrow Collection of blood in Anterior Chamber (AC).

2. Iris signs :

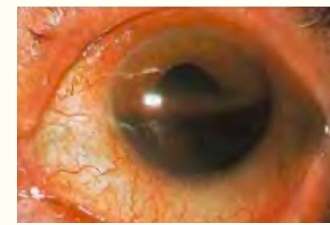
- Iridodonesis : Trembling iris.
- Iridodialysis : Detachment of root of iris from ciliary body.

- D shaped pupil.

- Diplopia d/t 2nd pupil.



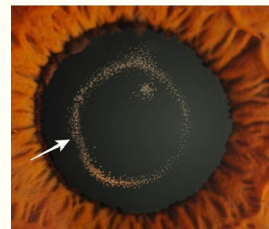
Iridodialysis



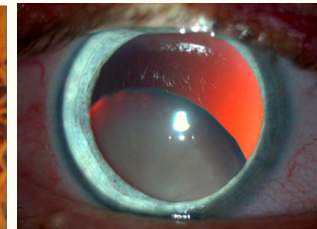
Hyphema

3. Lens signs :

- Phacodonesis : Trembling lens.
- Rosette shaped cataract.
- Vossius ring : Ring of pigment (D/t pupil striking the lens).
- Ectopia lentis : Subluxation of lens.



Vossius ring



Ectopia Lentis

4. Fundus/retinal signs :

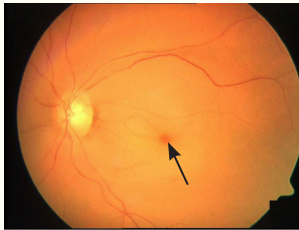
- Cherry red spot at macula : Fluid accumulation in all of retina except macula in trauma (Berlin's edema).

- Retinal Detachment (RD) : m/c **rhegmatogenous RD**.
- Commotio retinae : Pale fundus.
- Traumatic optic neuropathy : Causes 1° optic atrophy.
- **vitreous hemorrhage** : m/c cause in young adults.

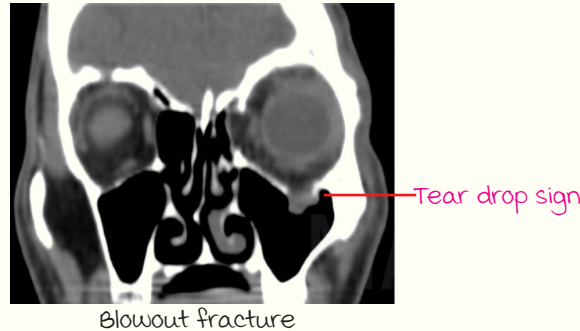
5. 2° open angle glaucoma:

- Angle recession glaucoma.
- Ghost cell glaucoma.

Note :

Cherry red spot at macula	
mnemonic : Cherry Trees Never Grow Tall in Sand, Mud & Grime	
<ul style="list-style-type: none"> • Central retinal artery occlusion (CRAO) • Trauma (Blunt) • Niemann-Pick disease • GMI gangliosidoses • Tay-Sachs disease • Sandhoff's disease • metachromatic leukodystrophy • multiple sulfatase deficiency • Gaucher's disease (Type 2 only) : Least common 	

Blunt Trauma to Orbit :



Complicated Cataract

00:30:15

Causes : mnemonic **UMAR**.

- **U**veitis (m/c).
- **m**yopia.
- **A**ngle closure glaucoma.
- **R**etinitis pigmentosa.

Appearance : Breadcrumb + Polychromatic lustre.

Site : Posterior subcapsular cataract.

Senile Cataract

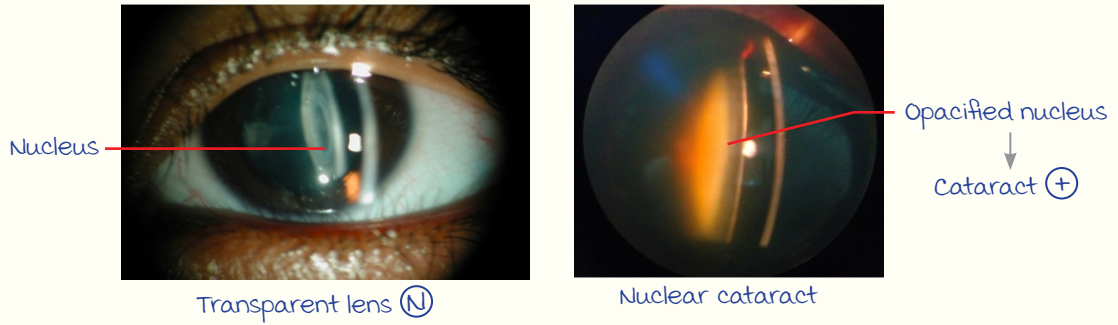
00:31:50

Age group : 50-70 years.

Types (Based on location) :

- a. Nuclear
- b. Cortical
- c. Posterior subcapsular
- d. Anterior subcapsular

----- Active space ----- **Nuclear Cataract :**



Slit lamp oblique illumination

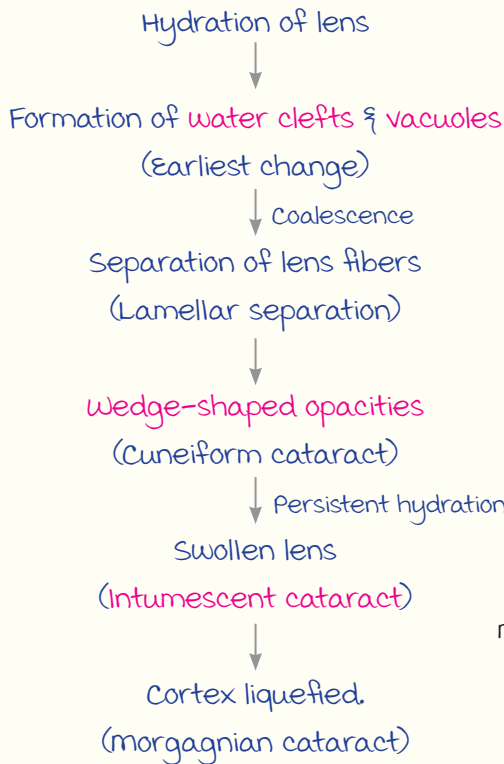
Pathogenesis : Sclerosis of lens → ↑ Refractive index.

Clinical Features :

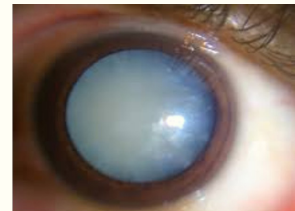- Induced myopia (Near-sightedness).
- **Second sight phenomenon** : Improved near vision.
- LOV : **Day > Night** (D/t central location; Pupil dilates in low light).
- xanthopsia : Yellow colored vision d/t discolored lens.

Cortical Cataract :

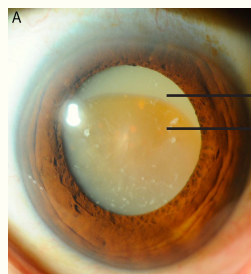
Pathogenesis :



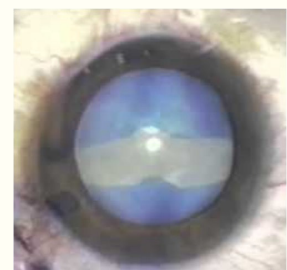
Cuneiform cataract
m/c inferonasally



Intumescent cataract
m/c complication :
Phacomorphic glaucoma
(2° AC glaucoma)



morgagnian/Hypermature cataract
m/c complication :
Phacolytic glaucoma
(2° OA glaucoma)



Argentinian flag sign
d/t **puncturing of**
swollen lens during CCC

Posterior Subcapsular Cataract :

----- Active space -----

Causes : mnemonic → **MNC Repay GST.**

- **myotonic** dystrophy
- **Neurofibromatosis**
- **Complicated** cataract
- **X-Rays**
- **Galactosemia**
- **Steroids (Systemic)**
- **Trauma (Blunt)**

Clinical Features :

- **Glare** → Difficulty in driving at night (m/c).
- max. LOV (Near > Far; Day > Night).

Note : **Topical steroids** → Glaucoma.

Anterior Subcapsular Cataract :

Rarest type.

Causes : **AACG**

- **Amiodarone**
- **Chlorpromazine**
- **Atopic dermatitis**
- **Gold deposits**

Surgical Management of Cataract

00:44:45

Surgical methods:

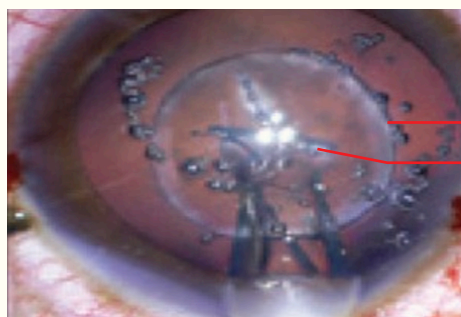
- **ICCE** : whole lens removed (No longer used).
- **ECCE** : Lens removed, capsule retained.

Techniques of **ECCE** :

	Site of Incision	Size of Incision
1. Conventional ECCE	Limbus	8-10 mm
2. Small Incision Cataract Surgery (SICS)	Sclera (Sclera-corneal tunnel)	5-7 mm
3. Phacoemulsification	Clear corneal	2.2-3.2 mm

4. **FLACS (Femtosecond Laser Assisted Cataract Surgery)** :

- Latest technique.
- Femtosecond : 10^{-15} sec.



CCC
Nuclear fragmentation } Laser used for 2 steps

Nd : Glass Laser

Principle → **Photodisruption**

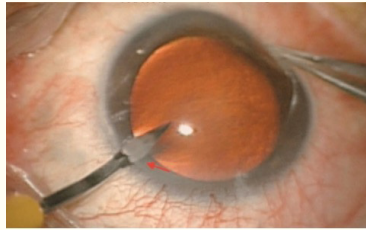----- Active space -----

Phacoemulsification :

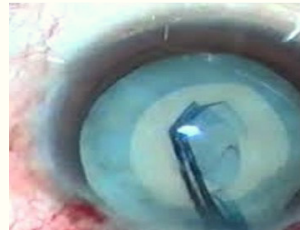
Principle :

Piezoelectric crystal at tip of phacotome $\xrightarrow{\text{Converts}}$ Ultrasonic energy $\xrightarrow{\text{to}}$ **mechanical energy (To & fro motion).**

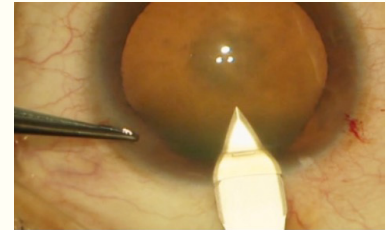
Steps:



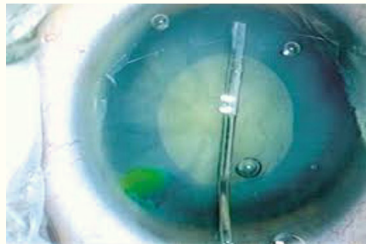
1. Side port incision
using MVR/15° blade



2. Staining the capsule + CCC
Dye : **Trypan blue**

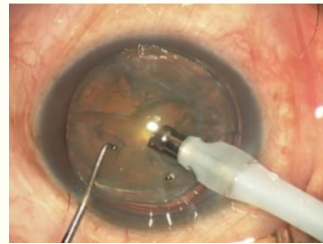


3. Main incision



4. Hydrodissection

Separation of cortex & capsule



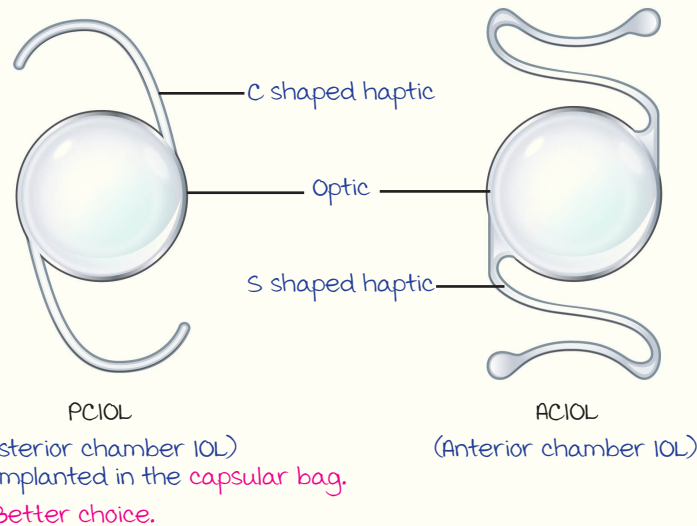
5. Nuclear fragmentation

6. Irrigation & aspiration
7. IOL implantation

Note : CCC \rightarrow Continuous Curvilinear Capsulorhexis.

Intra-ocular lens (IOL) :

Types of IOL :

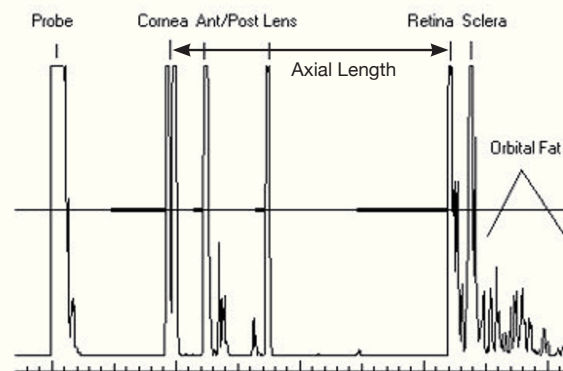


Biometry : Calculations of power of IOL to be implanted

1. Keratometry : **Corneal curvature.**

2. A-scan USG : Axial length/AP diameter of eye (Ⓝ AL ~ 24 mm).

----- Active space -----



3. IOL power calculation using SRK-T formula.

Complications of Cataract Surgery

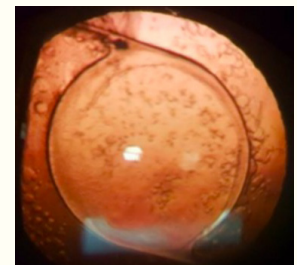
00:38:54

Operative :

- Posterior Capsular Rupture (PCR).
- Uveitis-Glaucoma-Hyphema (UGH) Syndrome → d/t ACIOL.
- Vitreous loss.
- Expulsive choroidal hemorrhage : Bleeding from choroidal artery.
- Descemet membrane detachment : Reattached by injecting air bubble or gas in AC → Descemetopexy.

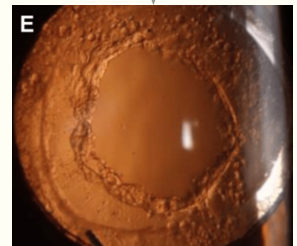
Postoperative :

- Posterior capsular opacification (m/c) :
 - Occurs 6-12 months postop.
 - Types
 - Elschnig's pearls (90%)
 - Sommering's ring (10%)
- Retinal detachment.
- Irvine Gass/vitreous wick syndrome :
 - 6-10 weeks postop.
 - Cystoid macular edema + bullous keratopathy d/t vitreous touch.
- Displacement of IOL :
 - Sunset syndrome : Inferior subluxation.
 - Sunrise syndrome : Superior subluxation.
 - Lost lens syndrome : Complete dislocation.
- Toxic Anterior Segment Syndrome (TASS).
- Flat/shallow AC :
 - wound leak.
 - Ciliary choroidal detachment.
 - Pupillary block glaucoma.
 - malignant glaucoma.



Elschnig's pearls

Rx

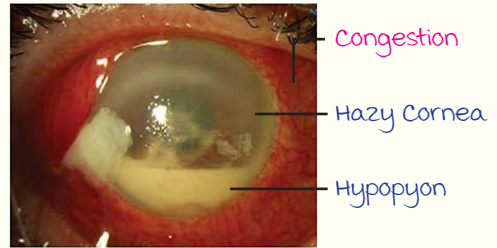


Nd YAG laser posterior capsulotomy

----- Active space ----- Endophthalmitis (Starts intra-op, extends post-op) :

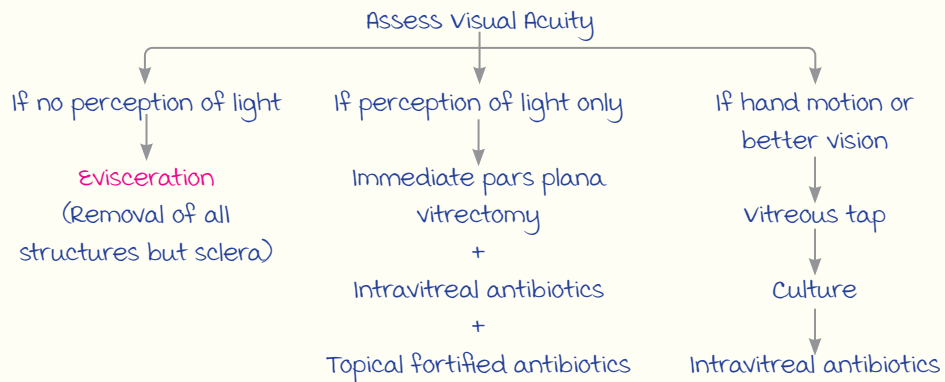
- **Suppurative** inflammation of all structures **except sclera**.
- Causes :

Type	m/c Pathogen
Early postop (<7 days)	CONS (<i>Staphylococcus epidermidis</i>)
Late postop (>6 weeks)	<i>Propionibacterium</i>
Traumatic	<i>B. cereus</i>
Endogenous	<i>Klebsiella, Candida</i>



Presentation of endophthalmitis

- C/f : Pain, redness, LOV + vitritis.
- Rx :

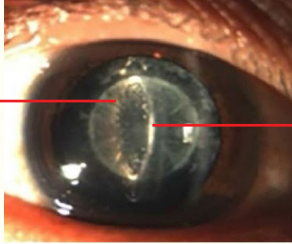


Note : Systemic antibiotics have no role.

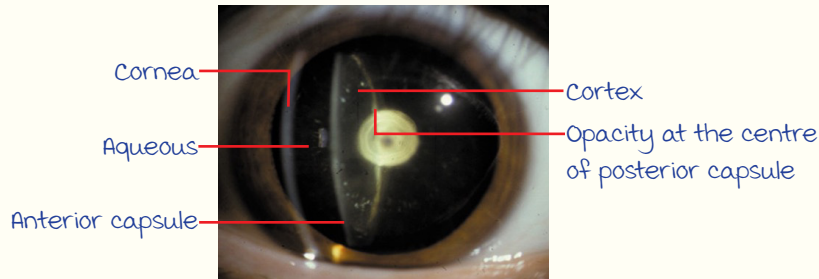
Congenital Cataract

01:03:00

Types :

	Infantile cataract	Developmental cataract
Age at presentation	< 1y	> 1y
LOV	Severe	minimal
m/c type	<p>Lamellar/zonular cataract</p> 	<p>Blue dot/punctate cataract (A/w Downs syndrome)</p>
Rx	Immediate surgery	-

----- Active space -----



Posterior Polar Cataract

- Onion ring/whorled appearance.
- A/w **Mittendorf dots**.
(Remnants of hyaloid artery).

Miscellaneous

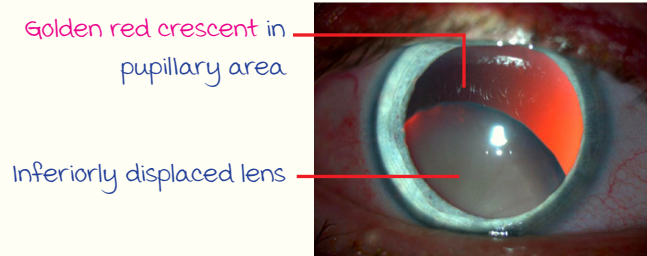
01:05:50

Ectopia Lentis :

Subluxation of lens d/t breakage of zonules.

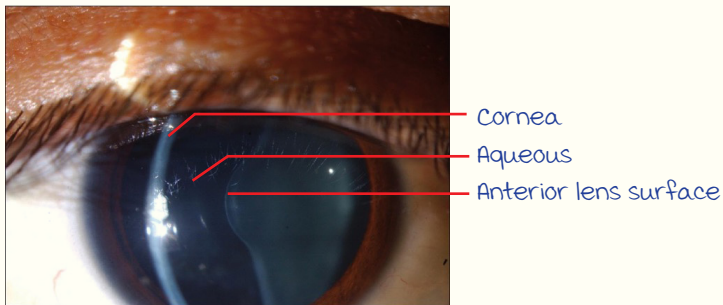
Causes :

- **Blunt trauma** (m/c).
- marfan's syndrome (Superotemporal subluxation).
- Homocystinuria (Inferonasal subluxation).
- Weill-marchesani syndrome (Anterior subluxation).



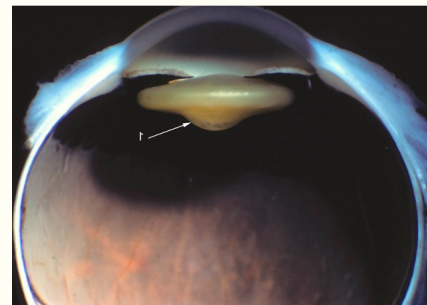
Clinical features : Diplopia d/t differential refractive power.

Lenticonus :



Anterior Lenticonus

Causes : **Spina bifida**, **Alport syndrome**, **Waardenburg syndrome**



Posterior Lenticonus

Cause : **Lowe syndrome**

GLAUCOMA

----- Active space -----

Pathophysiology and Types

00:00:20

PATHOPHYSIOLOGY

Optic neuropathy :

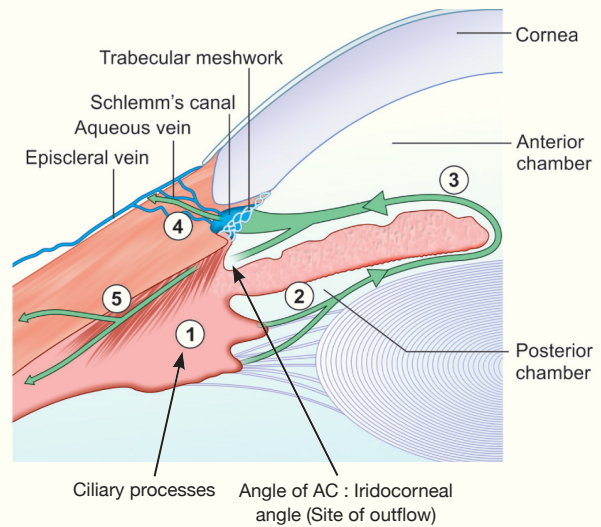
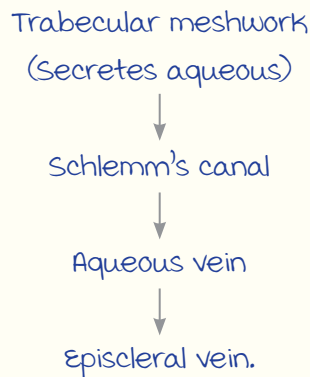
- Optic disc changes : Progressive, **characteristic**.
- Visual field defects : **Irreversible**.
- IOP : Normal/raised (Normal : 11-21 mmHg).

Glaucoma can occur by either **↑ production** or **↓ clearance** of aqueous.

Flow of Aqueous :

Trabecular and uveoscleral outflow.

Trabecular outflow :



	Open Angle Glaucoma (OAG)	Angle Closure Glaucoma (ACG)
Angle b/w iris & cornea	wide	Narrow
Pathology	Defective trabecular meshwork	Anterior displacement of iris
Anterior chamber	Deep	Shallow
Rx	<ul style="list-style-type: none"> • Trabeculoplasty • Trabeculectomy 	<ul style="list-style-type: none"> • Iridectomy • Iridotomy

Investigations

00:05:37

----- Active space -----

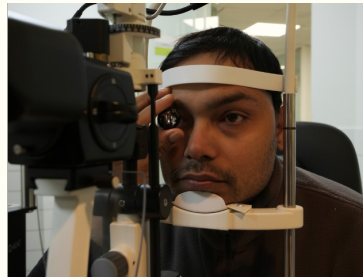
Optic Disc Examination :

Direct ophthalmoscopy :

- magnification : 15 times.
- Visualizes central fundus.
- Disadvantage : No binocular vision (No depth perception).

Slit lamp biomicroscopy :

magnification : $\oplus 90 \text{ D}$ lens



90D Examination

Visual field examination :

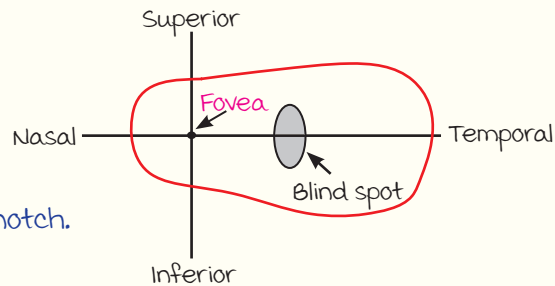
Perimetry :

1. Kinetic (moving targets) : Not preferred.
2. Static (Idle targets) :

Eg : Humphrey Field Analyzer (HFA).

Normal visual field :

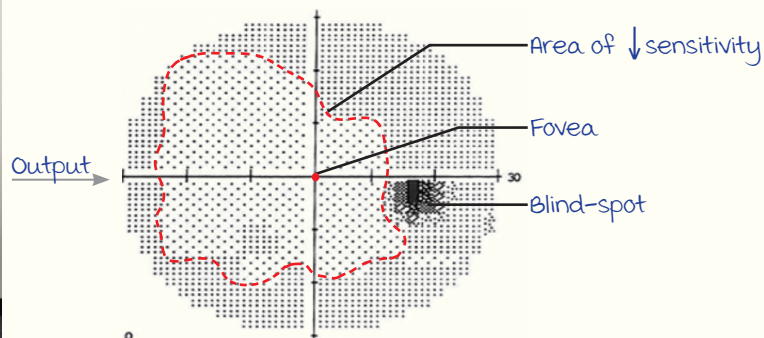
- Horizontally oval with an infero-nasal notch.
- Superior : minimum.
- Temporal : maximum.



Humphrey Field Analyzer :



HFA machine

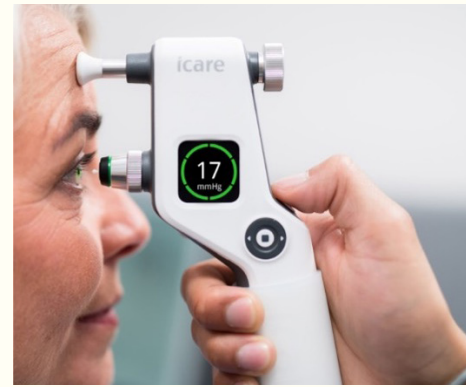

----- Active space -----

IOP measurement/Tonometry :**1. Indentation tonometry :**

Schiøtz tonometer

Not preferred d/t variability



Rebound tonometer

Choice for self-monitoring

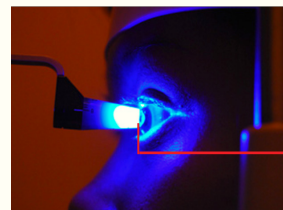
2. Non-contact tonometry : Choice for screening in camps.**3. Transpalpebral tonometry (Diaton, Proview) : visualized through eyelid (Not commonly used).****4. Applanation tonometry : m/c done.**Principle : **Imbert Fick law** → Pressure = Force/Area

Types : Fixed force (Not used) and fixed area.


Fixed area tonometers :

1. Goldmann's : Gold standard

- Corneal stain : Fluorescein dye.
- Cobalt blue light.

2. Mackey marg :Choice of tonometry in **edematous irregular cornea.**

Touches the cornea

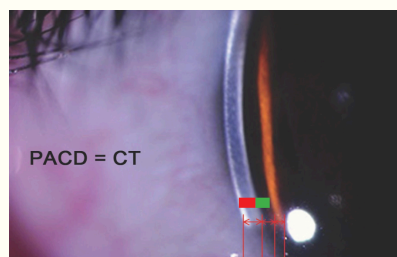


Inner margins of superior & inferior rings should touch

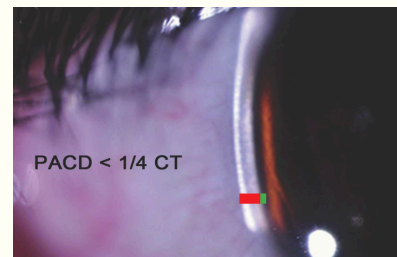
AT rings/mires

Examination of Angle of Anterior Chamber :**1. Van Herick's method :**

- Comparison of peripheral anterior chamber depth (PACD) & corneal thickness (CT).
- Performed in slit lamp.
- $PACD = CT$ → **Open angle.**
- $PACD < 1/4 CT$: Shallow AC → **closed/closing angle.**



PACD = CT



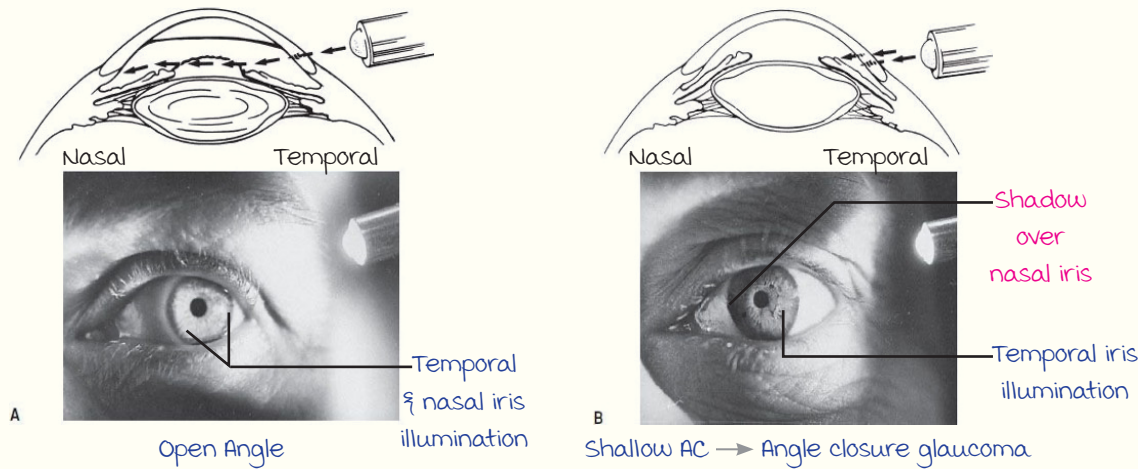
PACD < 1/4 CT

■ : CT

■ : PACD

2. Oblique Flashlight Test :

----- Active space -----



3. Gonioscopy : Best.

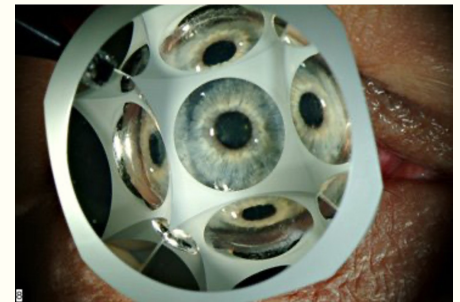
Principle : Overcomes total internal reflection.

C/I : Dilated pupil.

Structures seen :

Mnemonic : Can't see this stuff.

- | | | |
|-----------|---|--|
| Posterior | ↓ | <ul style="list-style-type: none"> • Ciliary body. • Scleral spur. • Trabecular meshwork. |
| Anterior | ↓ | <ul style="list-style-type: none"> • Schwalbe's line (Peripheral termination of Descemet's membrane). |



4 mirror Gonioscope

Primary Open Angle Glaucoma (POAG)

00:18:24

- Chronic disease.
- Age : >50 yrs.
- Family history ⊕.
- Genes : WDR 36, optineurin, myocilin.

Symptoms :

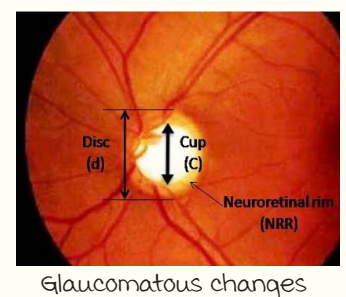
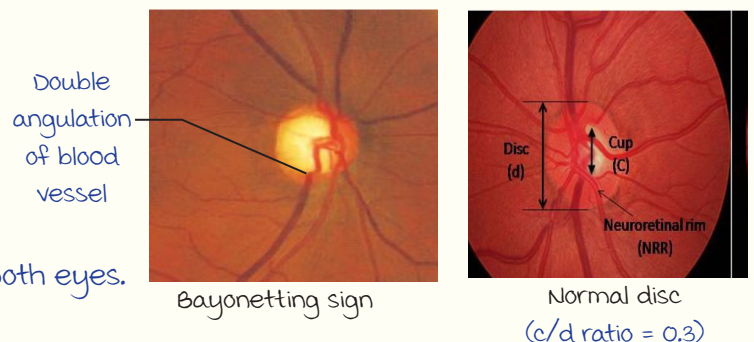
- Headache.
- Delayed dark adaptation.
- Frequent change in presbyopic spectacles.

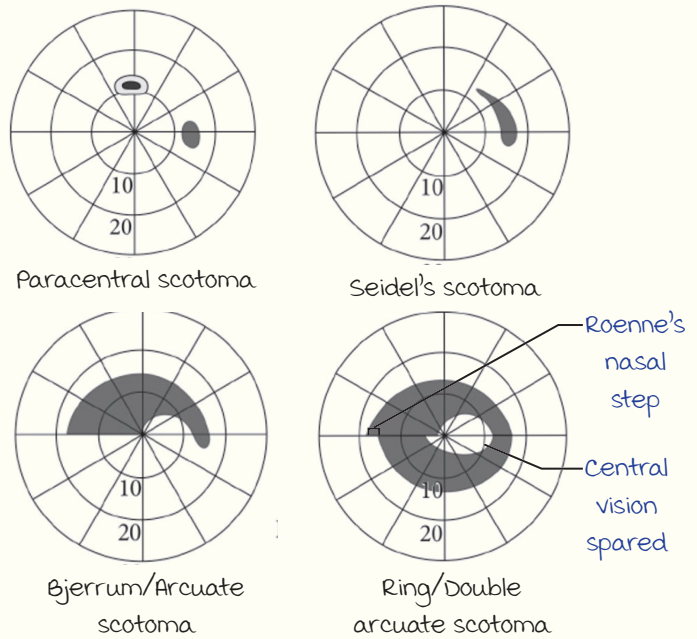
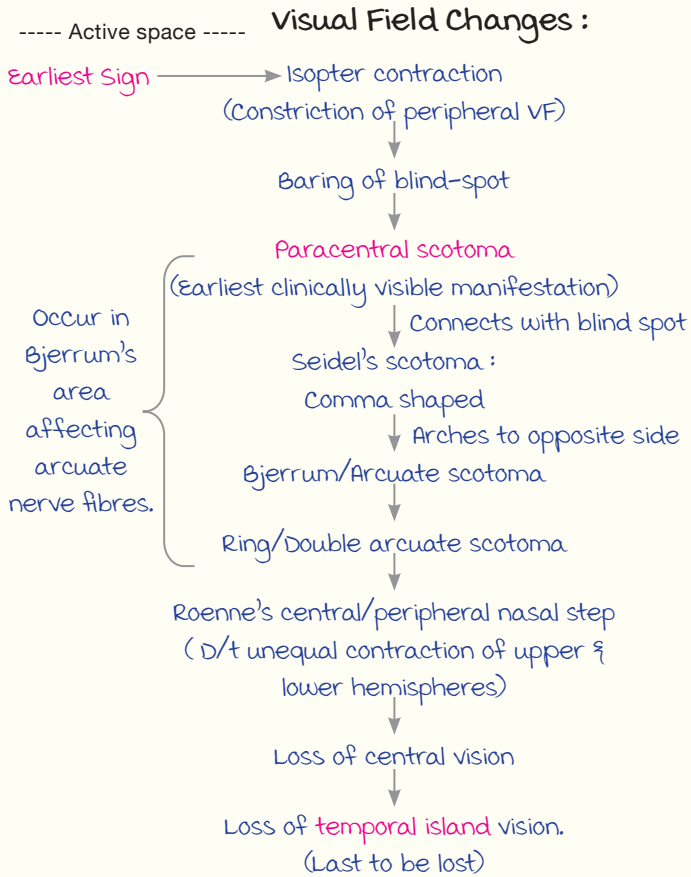
Signs :

IOP : >21 mmHg OR >5 mmHg difference b/w both eyes.

OD Changes :

1. Loss of neuroretinal rim (Inferior).
2. Vertical cupping (c/d ratio >0.5).
3. Bayonetting sign.
4. Lamellar dot sign.
5. Peripapillary atrophy.
 - α zone : Specific.
 - β zone : Also seen in myopia (As temporal myopic crescents).





Treatment :

medical mx : Topical drugs.

Drug	MOA	s/e
Prostaglandin $F_{\alpha\alpha}$ ($PGF_{\alpha\alpha}$) Latanoprost (DOC) : OD dosage	↑ uveoscleral outflow	<ul style="list-style-type: none"> • Hypertrichosis (↑ Growth of eyelashes) • Hyperpigmentation of iris • Cystoid macular edema • Uveitis
β blockers : Timolol (Non-selective β blockers)	↓ Aqueous production	<ul style="list-style-type: none"> • Corneal anesthesia • Nasolacrimal duct (NLD) blockage • Blepharoconjunctivitis
α -agonists : Apraclonidine	↓ Aqueous production ⊕ ↑ Trabecular outflow	<ul style="list-style-type: none"> • Eyelid retraction • Mydriasis • Follicular conjunctivitis
Brimonidine	↓ Aqueous production	CNS suppression d/t crossing of BBB <ul style="list-style-type: none"> • Drowsiness • Apnea • Depression
Carbonic anhydrase inhibitors : Acetazolamide	-	Emergency drug
Rho Kinase inhibitors : Netarsudil	↓ Aqueous production ⊕ ↑ Trabecular outflow	-

Surgical mx : ↑ Trabecular outflow.

1. Laser trabeculoplasty :
 - Photocoagulation with argon laser.
 - TOC for prophylaxis in other eye.
2. Trabeculectomy : Best Sx.
3. Non-penetrating Sx
 - Visco canalostomy.
 - Deep sclerectomy.
4. Seton Sx/Drainage devices :

In resistant cases

 - Express mini shunt.
 - Maltena devices.
5. MIGS (minimally Invasive Glaucoma Sx).

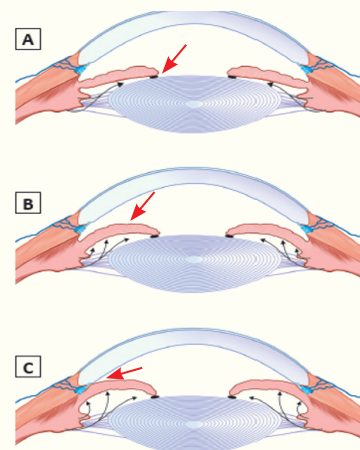

----- Active space -----

Primary Angle Closure Glaucoma

00:29:00

Acute disease.

Pathogenesis :



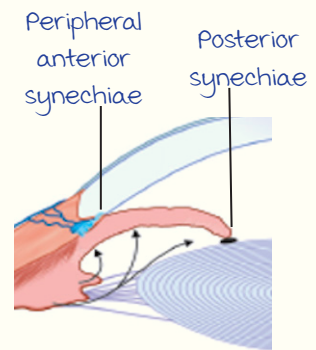
Clinical Features :

- Headache.
- Severe eye pain : IOP >40 mmHg (Rock hard eye in digital tonometry).
- High IOP disrupts the endothelium → Corneal edema.
- Distorted vision : D/t hazy cornea.
- Redness of eye.
- Vomiting.
- Halos around lights : Prismatic dispersion d/t corneal edema.

----- Active space -----

Signs :

- Eclipse sign : Shadow over nasal iris. (Oblique flashlight test)
- **Vogt's triad** :
 - Iris atrophy.
 - Posterior synechiae (Adhesion b/w pupillary margin & lens).
 - vertically oval mid-dilated pupil (D/t iris atrophy), which is fixed.



Note : ACG is precipitated in dark places (Eg : movie halls).

Treatment :

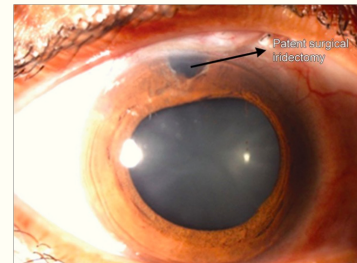
Initial Rx :

- IV mannitol (DOC)
- Oral acetazolamide } ↓ IOP
- Pilocarpine eyedrops (miotic) : Given after ↓ IOP; Pulls iris to center and open angle.

Definitive Rx :

Laser iridotomy : TOC.

- Nd-YAG Laser.
- B/w 11 o'clock & 1 o'clock.
- Equalizes pressure.



Laser iridotomy

Congenital Glaucoma

00:37:10

Signs :

1. Buphthalmos :

Enlarged eyeballs:

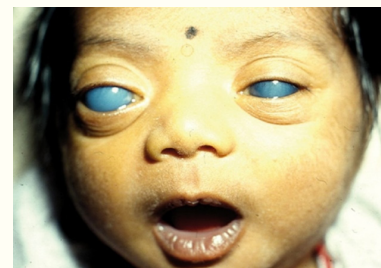- Deep AC.
- ↑ Axial length → myopia.
- Corneal diameter >13 mm.
- Blue sclera.

2. Haab's striae

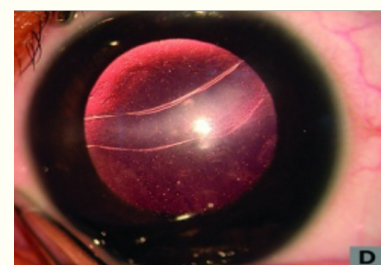
3. Hazy cornea : **Earliest sign.**

Symptoms :

- Blepharospasm
- Photophobia
- Lacrimation



Blue sclera



Haab's striae

Treatment :

- Trabeculectomy + trabeculotomy : TOC
- Goniotomy : If cornea is clear.

----- Active space -----

Secondary Glaucoma

00:39:25

TYPES**1. Lens Induced :**

- Phacomorphic : Intumescent cataract.
- Phacolytic : morgagnian cataract.

2. Pigmentary :

- Presents as 2° open angle glaucoma.
- Krukenberg spindles : Characteristic.

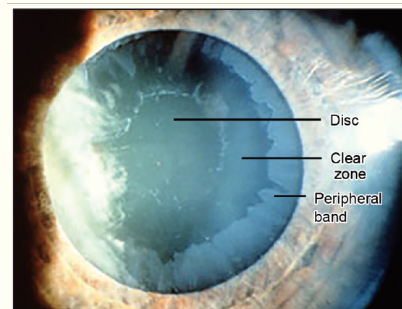
3. Pseudoexfoliation :

m/c cause of 2° open angle glaucoma.

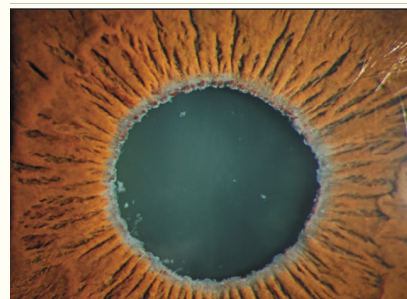
Characteristic Signs :

Target sign : Deposit of exfoliative material on lens.

Flocks : Deposit of pseudoexfoliative material on pupillary margin.



Target sign



Flocks

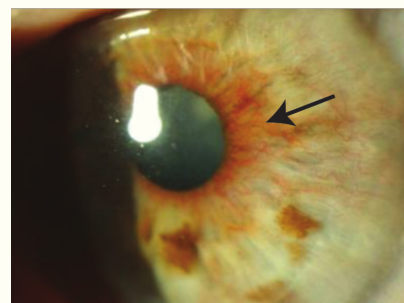
Neovascularization of Iris/Rubeosis Iridis :

Causes :

- Proliferative Diabetic Retinopathy (PDR).
- Ischemic CRVO.

Progression :

Hyphema \rightarrow 2° OAG (AKA neovascular glaucoma).



OPTICS AND REFRACTION

----- Active space -----

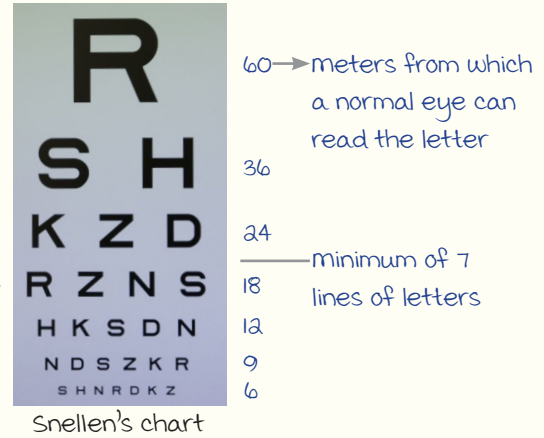
Tests for Vision

00:01:04

TESTS FOR FAR VISION

1. Snellen's Chart :

- Distance of examination : 6 metres.
- Normal : 6/5, 6/6.
- Least vision : 1/60.
 - 1/6 → Finger counting (FC) → Hand movement (Hm) → Perception of light (PL)




Principle :


Each letter subtends an angle of 5 minutes of arc at nodal point of eye when viewed from its respective distance.

2. Bailey-Lovie/Log chart

Not used in India.




3. Landolt C-Ring




4. Snellen's E-Chart

If pt. is illiterate



Tests Used in Infants :

1. Optokinetic nystagmus :




OKN drum

Catford drum

The child normally focuses on alternating light & dark bands

2. Preferential looking test :



Teller acuity cards

Keeler gratings

The child prefers to look at the patterned areas

3. Blink reflex :

- Blinks on exposing eye to light.
- Present since birth.

4. menace reflex :

- Any object brought close to the child's eye → Child moves away.
- Develops at 4 to 6 months of age.

5. Cardiff Acuity Test




----- Active space -----

TESTS FOR NEAR VISION :

Distance of examination : 30 to 35 cms.

1. Snellen's Near Chart :

- Best near vision : N_6 .
 - Worst near vision : N_{36} .
- m/c used.



Snellen's near chart

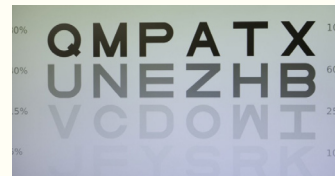2. Jaeger's Chart :

J_1 to J_7 vision.

TEST FOR CONTRAST SENSITIVITY :

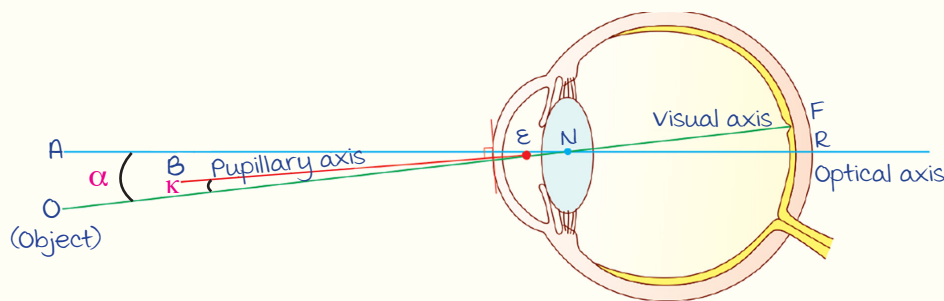
Pelli Robson Chart :

Used in case of cataract, where contrast vision is lost early.



Normal Optics of Eye

00:09:05



Axes :

1. Anatomical axis : \overline{ANR} .
2. Visual axis : \overline{OENF} .
3. Pupillary axis : \overline{BE} (Axis to the centre of the pupil).

Angles :

1. Kappa (κ) : B/w pupillary and visual axes.
2. Alpha (α) : B/w anatomical and visual axes.

----- Active space -----

Gullstrand's Schematic Eye :

Purkinje images :

4 refractory surfaces in the eye based on the reflections of light.

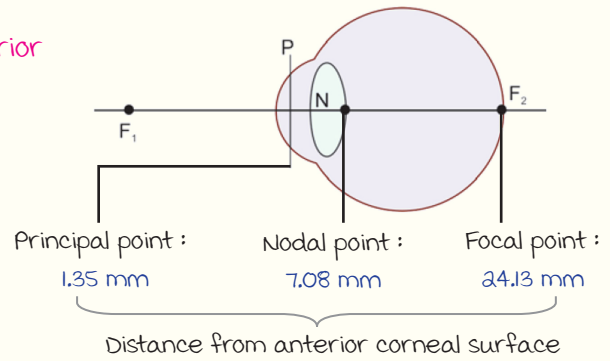
Purkinje Surfaces	I	II	III	IV
Site	Cornea		Lens	
	Anterior	Posterior	Anterior	Posterior
Power	+48.8 D (max)	-5.88 D	+19 D	

Listing's Reduced Eye :

- All elements measured from **anterior corneal surface**.
- Power of eye : **58.6 D**.

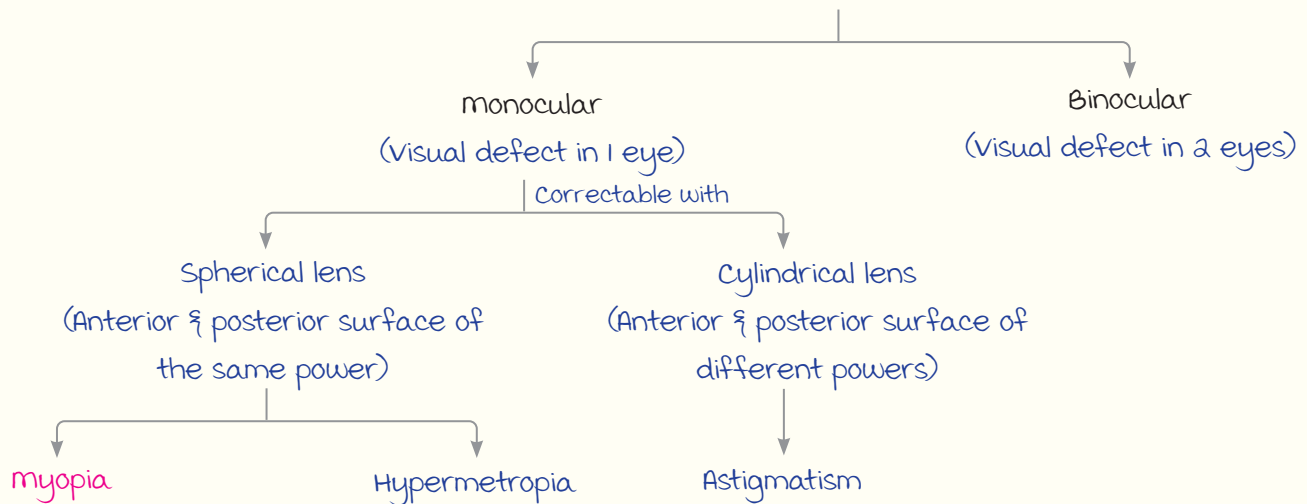
Factors determining power :

- Curvature of anterior corneal surface.
- Length of eyeball.

**Refractory Error**

00:12:09

Types :



	myopia	Hypermetropia
Power	more (Image in front of retina)	Less (Image behind the retina)
Corrective lens	'-'/Concave (Diverging)	'+'/Convex (Converging)
Axial length	↑ (Buphthalmos)	↓
Curvature	↑	↓
Refractory index	↑ (Nuclear cataract)	↓
Position of lens	Anterior (Weill marchesani syndrome)	Posterior

----- Active space -----

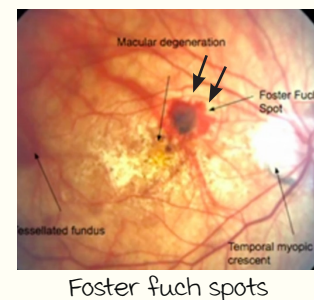
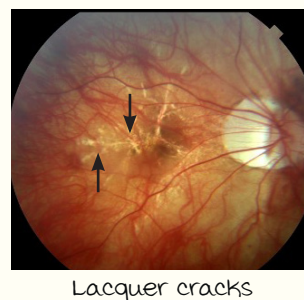
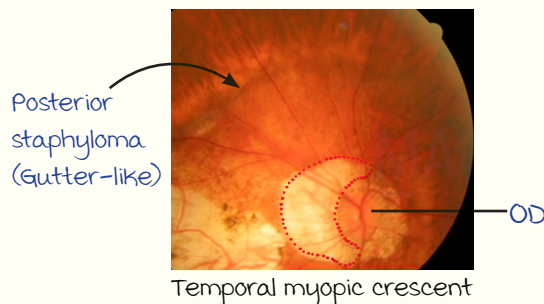
Note : 1 mm ↑ in axial length = 3D myopia.

Myopia

00:15:40

Fundus signs : Only seen in **pathological myopia** (>6D).

- Temporal myopic crescent : Choroidal & retinal atrophy.
- **Posterior staphyloma**.
- Lacquer cracks : Break in Bruch's membrane.
- Foster-Fuch's spots : Bleeding at the macula.
- Vitreous hemorrhage.
- Retinal detachment : Pathological myopia is the m/c cause of **rhegmatogenous retinal detachment**.

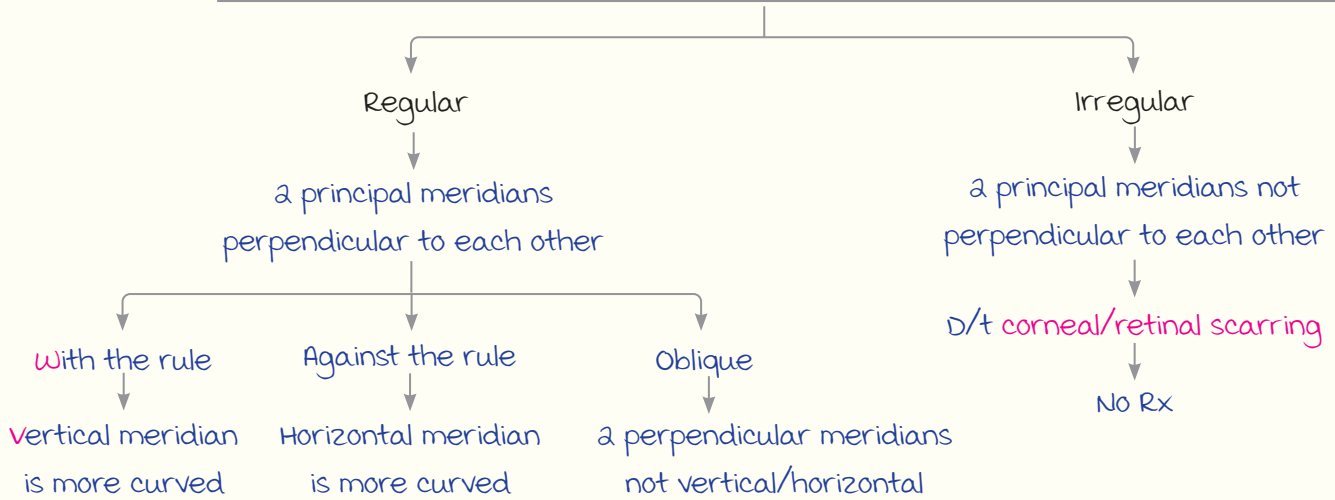


Surgical correction of myopia :

- Radial keratotomy (PRK) : multiple peripheral corneal incisions given → Stretches and flattens the cornea → ↓ Converging power.
- LASIK : **excimer laser** → Argon (Ar) & fluoride (F).
- SMILE (Small Incision Lenticule Extraction) : **Nd:Glass laser**.
- ICL (Implantable Collamer Lens) :
 - If power >8D.
 - Site of implantation : Sulcus (Space between iris & posterior chamber).
- INTACS (Intracorneal stromal ring segment).

Astigmatism

00:21:00



Treatment : **Cylindrical glasses/toric contact lens.**

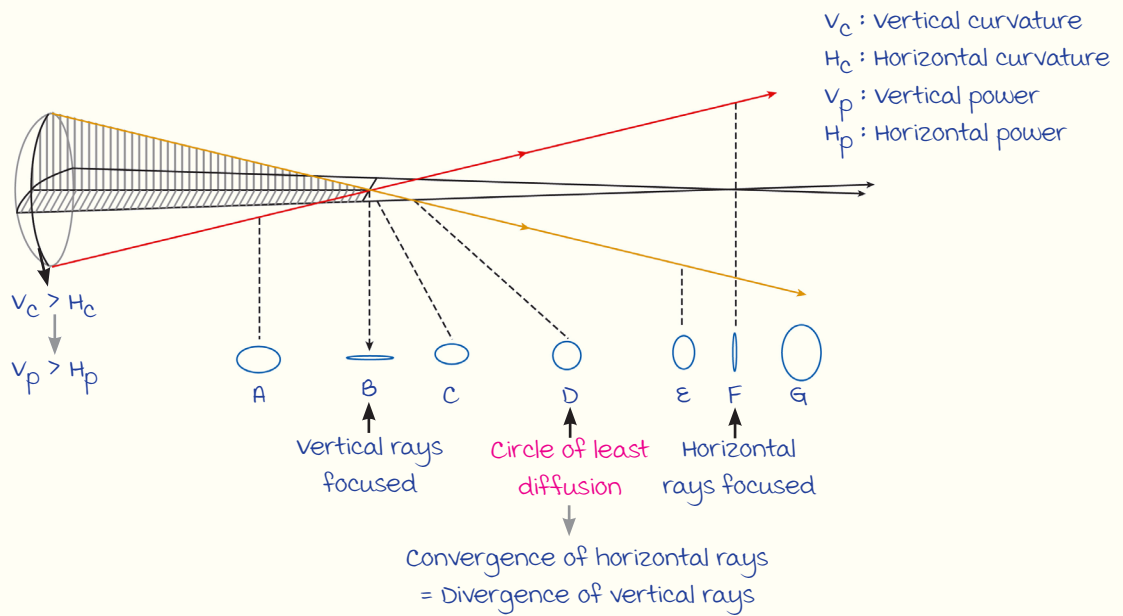
Axis determination :

	180°	90°
With the rule	Concave (-)	Convex (+)
Against the rule	Convex (+)	Concave (-)

mnemonic : **with CV, against VC.**

Sturm's conoid :

Configuration of light rays when refracted from a toric surface.



Correction of Refractory Errors

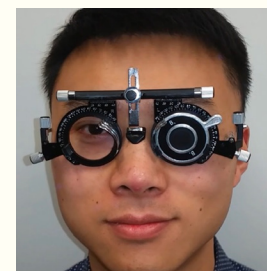
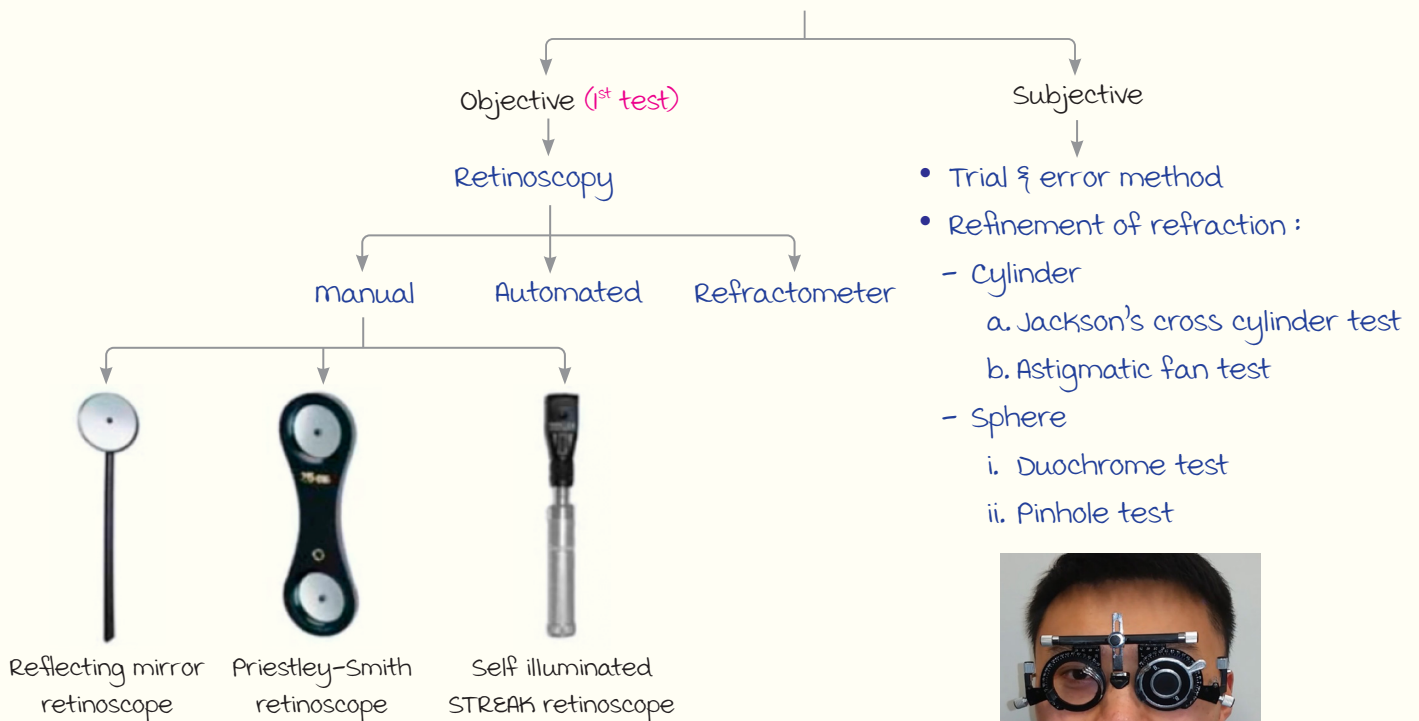
00:26:10

----- Active space -----

Prescription of Spectacles :

Lens	Use
⊖ Spherical	myopia
⊕ Spherical	Hypermetropia
⊖ Cylinder	Simple myopic astigmatism
⊕ Cylinder	Simple hypermetropic astigmatism
⊖ Spherical/⊖ Cylinder	Compound myopic astigmatism
⊕ Spherical/⊕ Cylinder	Compound hypermetropic astigmatism
⊖ Spherical/⊕ Cylinder OR ⊕ Spherical/⊖ Cylinder	Mixed astigmatism

Determination of refractory errors :



Trial & error method

Streak Retinoscope :

- m/c used.
- Light produced in vertical/horizontal beams.
- Distance of examination : 1 mt.
- method : Comparing movement of red streak to movement of retinoscope.

----- Active space -----

	Against	No movement	With
Power	>1 D myopia	1 D myopia	<1 D myopia
Retinoscopy value	variable	Zero	variable

Can also be either emmetropia/hypermotropia.

Retinoscopy values :

Correction factors (C) :

1. Distance (d) of examination : $C_1 = 1/d$.
2. Tonus allowance of cycloplegic drug (To neutralize accommodation power) :

Cycloplegics	C_a
Atropine	1
Cyclopentolate	0.75
Homatropine	0.50

Corrected retinoscopic value (RF) : $RF - C_1 - C_a$.

SUBJECTIVE ASSESSMENT :

Refinement for Cylindrical Lenses :

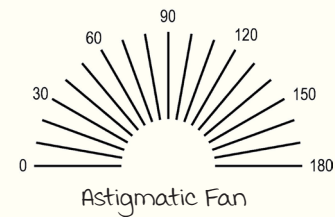a. Jackson Cross Cylinder (JCC) test :

- - 0.5 D sph/+ 1.0 cyl
 - - 0.25 D sph/+ 0.5 cyl
- } Combinations used

b. Astigmatic fan : Power refined till pt. can see all the axes well.




Jackson's Cross Cylinder



Astigmatic Fan

Refinement of Spherical Lenses:

1. Duochrome test :



2. Pinhole test :

Eliminates peripheral light rays, allows central light rays

↓ Placed in front of eye

Visual acuity

Improves

Residual refractory error.

Decreases

macular disease.



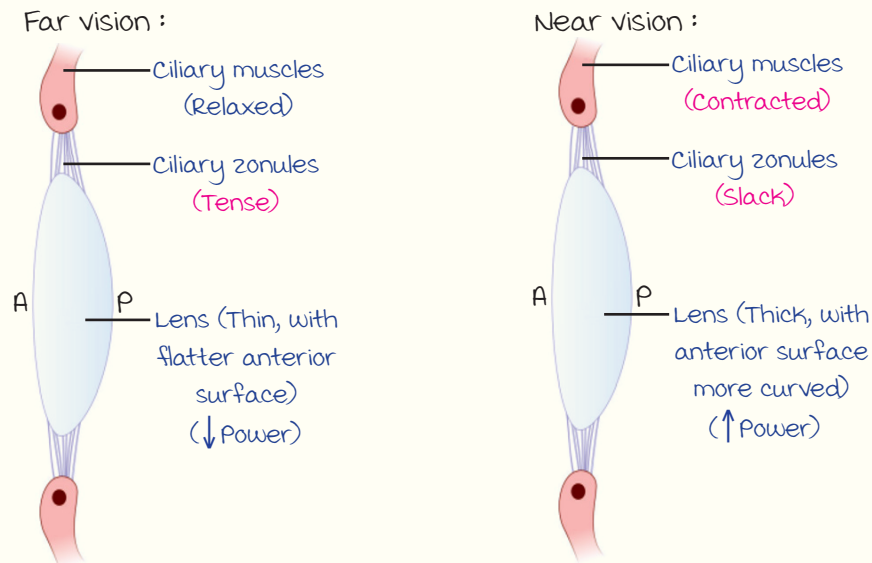
Size of hole : 1 mm in diameter

Accommodation

00:37:34

----- Active space -----

Helps near vision (Power needs to \uparrow).



Presbyopia :

- Physiological insufficiency of accommodation (Difficulty in near vision).
- Age : >40 yrs.

Treatment : Convex spectacle (+) (At 45y \rightarrow +1 D power)

Spasm of Accommodation :

- AKA Pseudomyopia.
- Issue with distant vision (D/t spasm of ciliary muscles).

Treatment : Cycloplegics \rightarrow Atropine (Relaxes ciliary muscle).

Newborn :

At Birth :

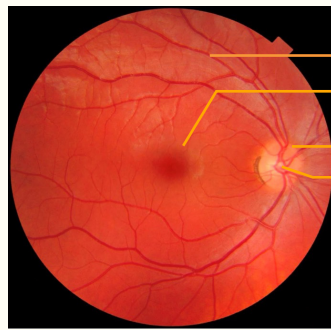
- Axial Length (AL) : ~ 17 mm (Smaller than normal).
- Refractory error : 2-3 D hypermetropia.
- Becomes emmetropic by 5-6 yrs.

RETINA

----- Active space -----

Anatomy

00:00:42



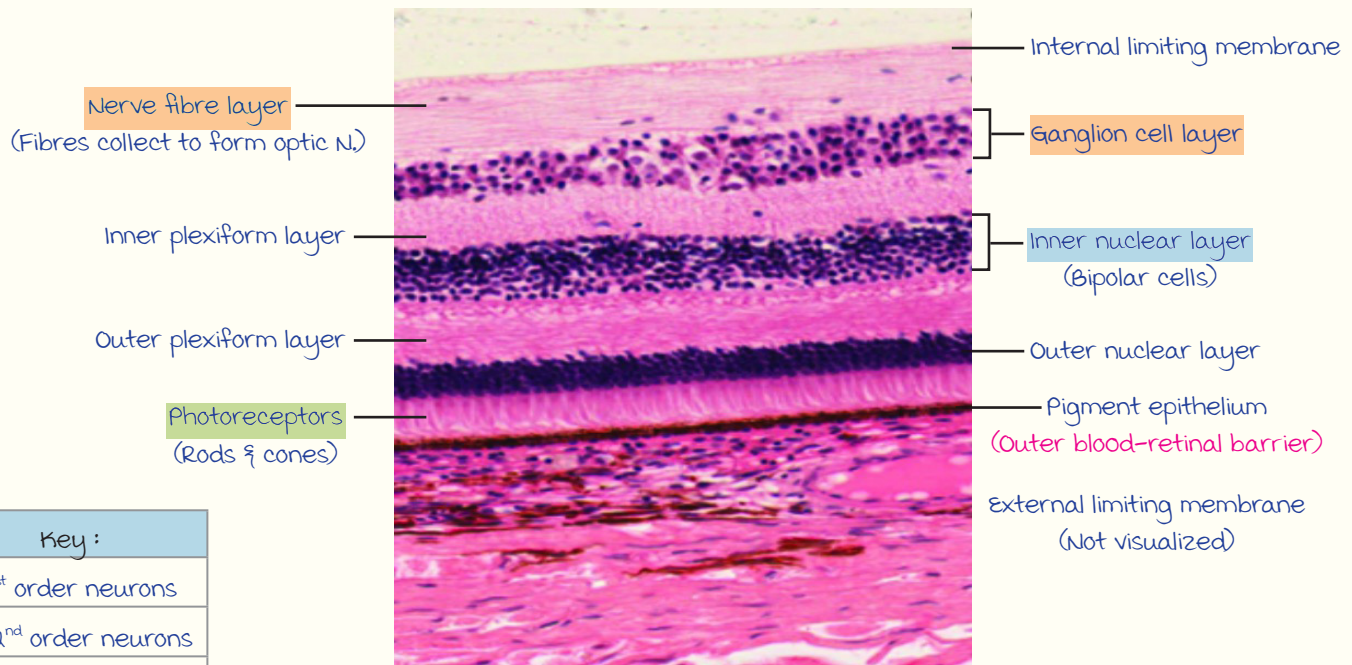
- Arc-like vessels
 - macula (Appears avascular & temporal to optic discs)
 - Neuroretinal rim
 - Optic cup
- Optic disc
- Diameter : 1.5 mm
 - Shape : Vertical oval
 - $\frac{c}{d}$ ratio : 0.3

Fundus :

- Vitreous } Transparent
- Retina } Transparent
- Choroid : Red

Ora serrata :

- Anterior termination of retina.
- Site of **intravitreal injection** : Anterior to ora serrata or 3-4 mm posterior to limbus. (Pierces sclera & pars plana)

Layers of retina (Inside to outside) : mnemonic **ING (IOP)_a**

Key :	
	1 st order neurons
	2 nd order neurons
	3 rd order neurons



Note : **Subretinal space** → Space b/w inner 9 layers & pigment epithelium.

Investigations

00:09:18

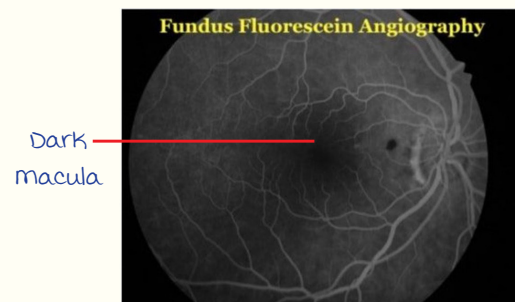
----- Active space -----

Ophthalmoscopy : To visualise fundus & retina (1st investigation).

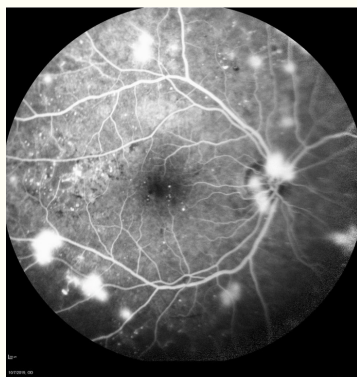
	Direct ophthalmoscope	Indirect ophthalmoscope
Appearance		
Operation	Hand-held	Worn around the head
External lens	No	Yes (Power : +20 D)
Distance of examination	As close to patient's eye as possible	Arm's length
Image	Virtual & erect	Real & inverted
magnification	15X	<ul style="list-style-type: none"> +20 D lens : 3X +14D lens : 5X
Area visualised	Small : <ul style="list-style-type: none"> Central fundus Optic disc & macula 	Large : <ul style="list-style-type: none"> Peripheral fundus Ora serrata
Field of view	10°	45° with +20 D lens
Area viewed	2 DD	8 DD

Fundus Fluorescein Angiography (FFA) :

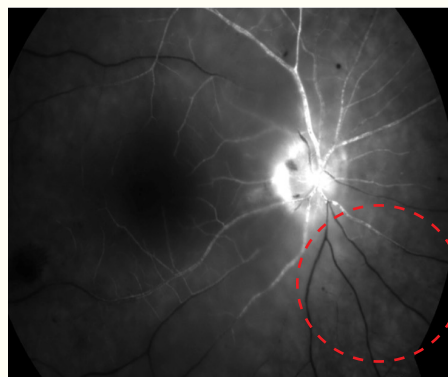
- Visualises fluorescent blood vessels.
- Diagnoses :
 - vascular disorders.
 - macular disorders :
 - Normal macula appears dark.



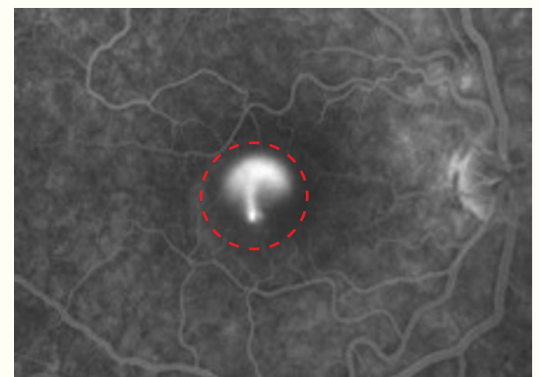
Normal FFA



Leakage from blood vessels



Blocked blood vessels



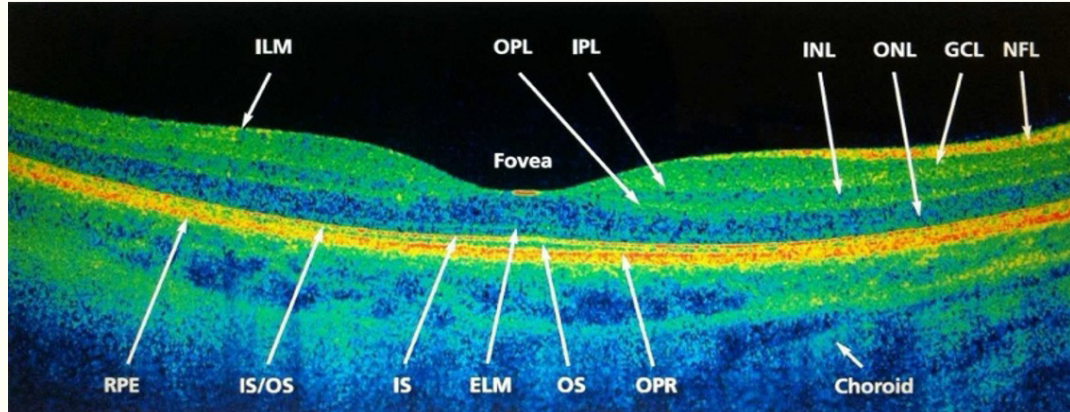
macular disorder

----- Active space ----- Indocyanine Green Angiography (ICGA) :

To visualise choroidal vasculature.

Optical Coherence Tomography (OCT) :

To visualise retinal layers.



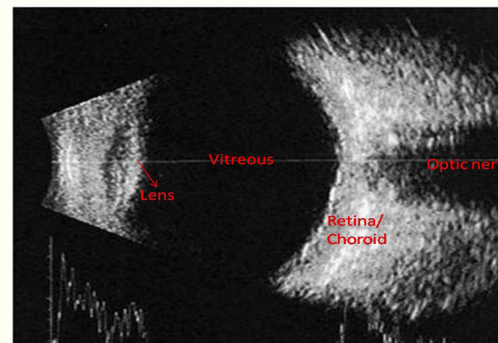
• RPE : Always red.

• Fovea : Depressed contour.

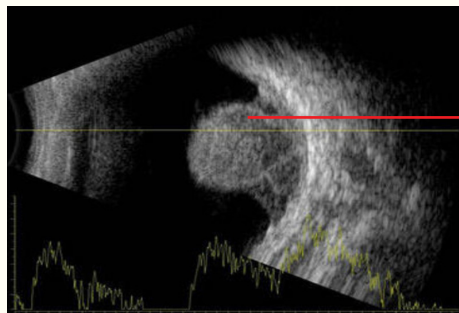
B (Brightness) Scan USG :

Structures observed :

- vitreous (black/hypoechoic).
- Retina } white/hyperechoic
- Choroid }

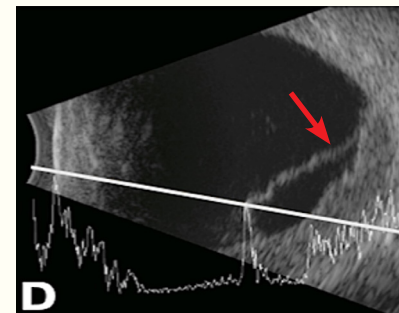


Pathologies on B-scan :



Choroidal melanoma

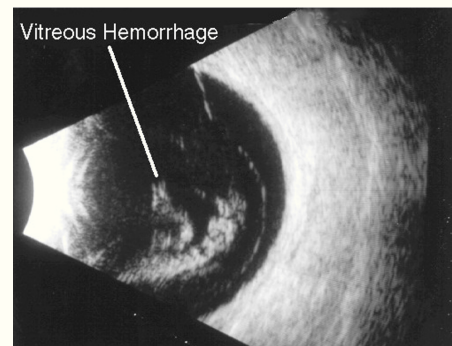
Collar stud/
mushroom
appearance



Retinal detachment

Vitreous Hemorrhage (VH) :

- m/c cause of VH :
 - Diabetic retinopathy.
 - Blunt trauma (young adults).
 - Eales disease (Recurrent)
- C/f : Blurring of vision/LOV.
- O/E : Pale fundus (Red glow obscured by hemorrhage).

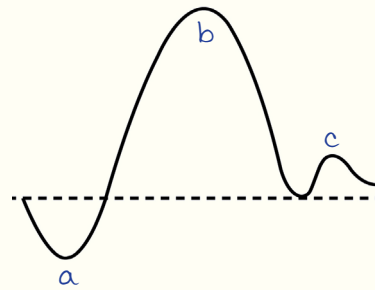


Electroretinography (ERG) :

- Records retinal **action potential**.
- Detects photoreceptor pathology.

Interpretation :

- a wave : Photoreceptors activity.
- b wave : Bipolar & muller's cells activity.
- c wave : metabolic activity of pigment epithelium.

**Electrooculography (EOG) :**

- Records retinal **standing potential** from outer retina. (Photoreceptors + Pigment epithelium)
- measurement : Arden's ratio = $\frac{\text{Light peak}}{\text{Dark trough}}$ (Normal > 185%)
- Detects photoreceptor pathology.

Retinoblastoma

00:23:20

Types :

- Non-hereditary (60%) : Always u/L.
- Hereditary : Non-familial (33%) and familial (7%).
- Sporadic (m/c) : Non-hereditary + Non-familial (93%).

Genetics :

- m/c inheritance : Autosomal Dominant (AD).
- Gene : RB on Chr. 13q14.

Knudsons 2 hit hypothesis : Tumor presents only on loss of heterozygosity.

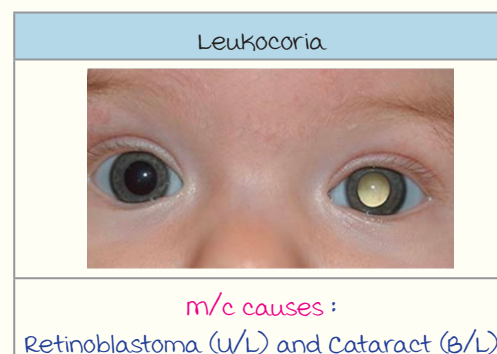
malignancy :

- m/c malignancy : PNET/pineoblastoma.
- m/c 2° malignancy : Osteosarcoma.

Clinical Features :

- **Leukocoria (m/c)**
- ↓
- white pupillary reflex
- Squint (2nd m/c).
- 2° glaucoma + Buphthalmos (3rd m/c)

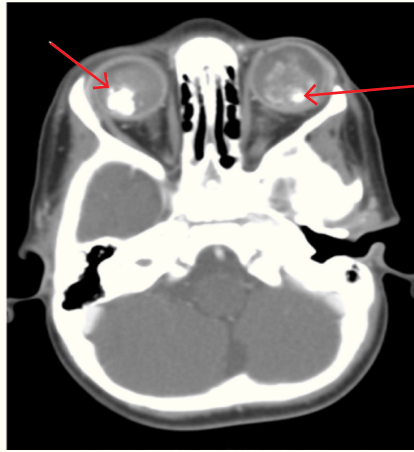Spread : **Direct** through optic nerve.



----- Active space -----

Investigations :

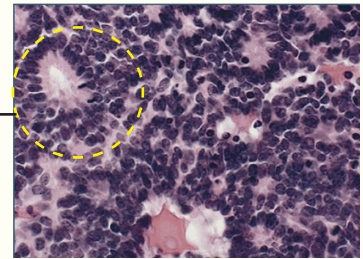
CT scan (IOC)



Calcified tumor
(m/c cause of
intraocular calcification)

Biopsy (Gold standard) :

- Sample : Optic nerve.
- Findings :
 - a. Homer wright rosettes (Pseudo-rosettes).
 - b. Fleurettes
 - c. Flexner wintersteiner rosette
 - Empty central lumen.
 - Surrounding cells with nucleus pointing centrally.

**Treatment :**

Enucleation (TOC) : Removal of eyeball + optic nerve.


Macular Disorders

00:29:25

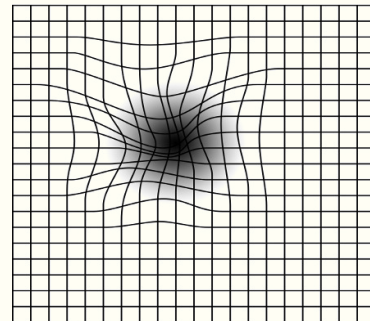
macula : Responsible for central vision (D/t fovea).

Tests :

1. Amsler's grid : Patient asked to look at the central dot.



Normal test : Straight lines



macular disorder: Wavy lines

2. Photostress test :

- ↑ Photostress recovery time in macular disorder.
- To differentiate macular with optic nerve disorders :
Normal photostress recovery time + LOV → Optic nerve disease.

MACULAR DISORDERS

----- Active space -----

Central Serous Retinopathy :

- Damage to Retinal Pigment Epithelium (RPE).
- Fluid in subretinal space.

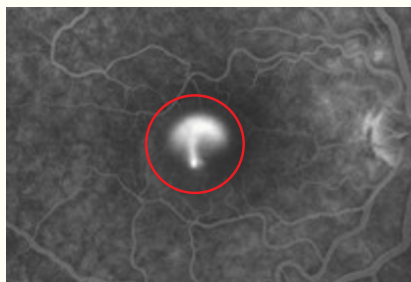
Risk factors :

- Steroids
- Cushing's syndrome.
- H. pylori infection.
- Type A personality.

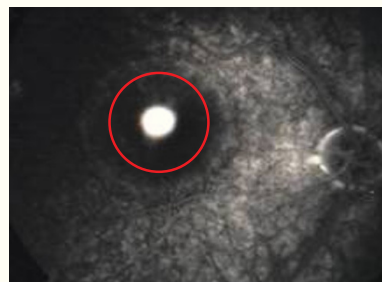Treatment :

- Self resolving, treat risk factor.
- Photodynamic therapy with verteporfin. } Not routinely done.
- Laser photocoagulation.
- Steroids c/i.

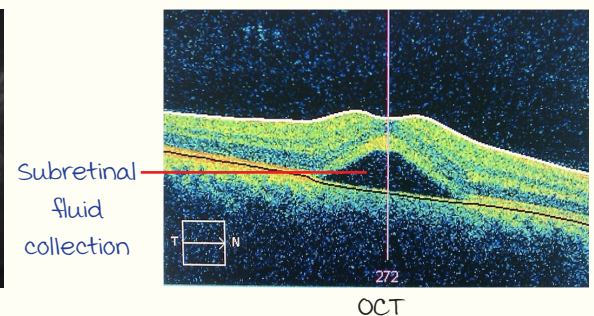
Investigations :



FFA : umbrella/smoke
stack appearance



FFA : Ink blot appearance



Subretinal
fluid
collection

OCT

Cystoid macular edema :

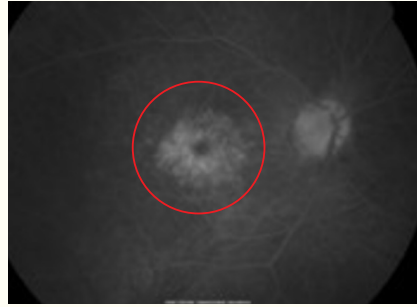
Fluid in outer plexiform layer.

Risk factors : mnemonic → RUN PRIDE.

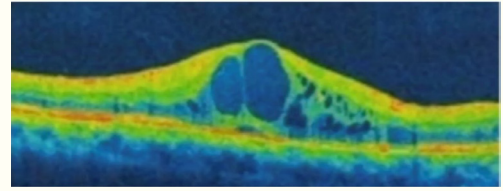
- Retinitis pigmentosa.
- Uveitis
- Niacin/nicotine.
- Prostaglandin analogues.
- Retinal vein occlusion.
- Irvine-Gass syndrome (Post-op cataract complication).
- Diabetic retinopathy.
- Epinephrine in aphakia.

----- Active space -----

Investigations :



FFA : Flower petal appearance



OCT : Cystic spaces

Treatment : Intravitreal steroids.

Age Related macular Degeneration (ARMD) :

a. Dry/Non-neovascular/Non-exudative

Stages :

- Early
 - Intermediate
 - Late → Geographic atrophy of RPE ⊕.
- } Drusen ⊕ (Yellowish eosinophilic deposits)

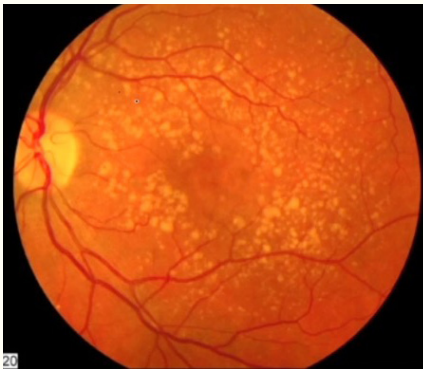Rx : Antioxidants

b. Wet/Neovascular/Exudative :

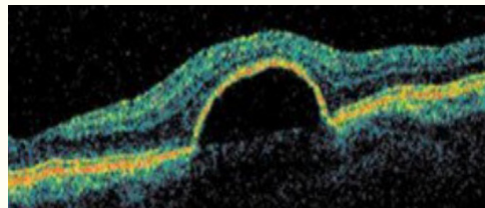
Signs :

- RPE detachment.
- Choroidal neovascularisation.

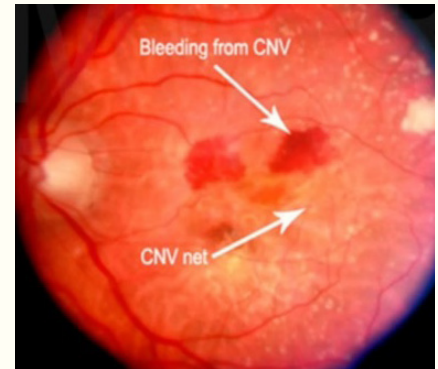
Rx : Intravitreal anti-VEGF drugs.



Drusens



RPE detachment



Choroidal neovascularisation

Fundus Dystrophies

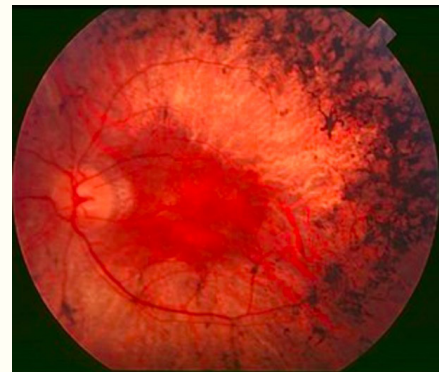
00:39:54

Retinitis Pigmentosa :

- Rod-cone dystrophy (Rods > cones).
- m/c inheritance : Autosomal recessive.
(m/c hereditary fundus dystrophy)

Clinical Features :

- Nyctalopia, ring/donut scotoma/ tunnel vision (Rods affected).
- Bony spicule pigmentation.
- Waxy, pale optic disc.
- Systemic association : Lawrence-moon-Biedl syndrome
- Arteriolar attenuation.



Bony spicule pigmentation

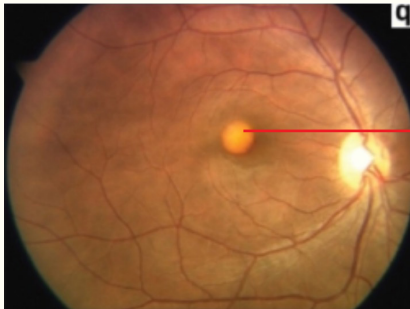
IOC : ERG (a wave absent).

Treatment : Genetic counselling (No Rx).

----- Active space -----

Best's macular Dystrophy :

- Cone dystrophy → Hemeralopia (Day blindness), central scotoma.
- Autosomal dominant.

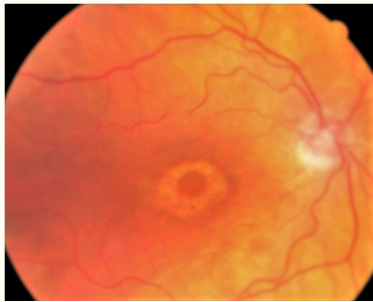


Egg yolk/vitelliform lesion
↓ Breaks
Pseudohypopyon/vitelliruptive lesion (Collection in AC)

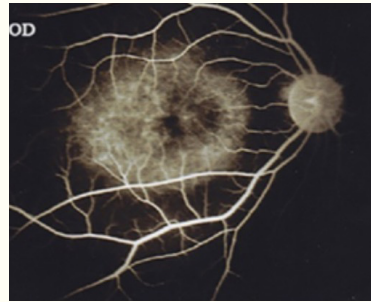
IOC : EOG (ERG normal, Arden's ratio <150%)

Stargardt Disease :

m/c cause of juvenile hereditary macular dystrophy.



Bull's eye maculopathy



FFA : Dark/silent choroid sign

Note : Bull's eye maculopathy also seen in chloroquine toxicity.

Vascular Disorders

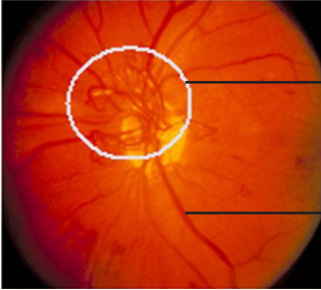
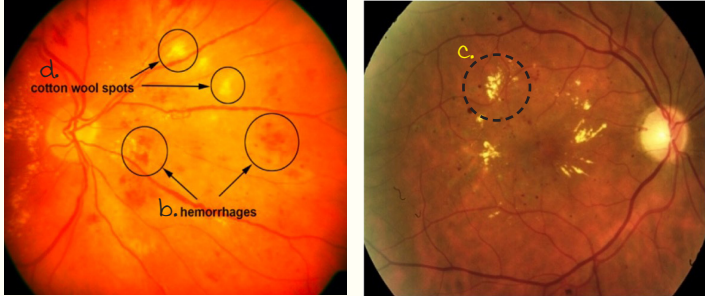
00:46:33

Diabetic Retinopathy :

Risk factor : Duration of DM.

Screening : → T₁ DM : 5 years after Dx.
→ T_a DM : Immediately on Dx.

----- Active space ----- Early Treatment Diabetic Retinopathy Study (ETDRS) classification :

	Proliferative DR (PDR)	Non-proliferative DR (NPDR)
Signs	<p>Neovascularisation :</p> <ul style="list-style-type: none"> NVD : At disc. NVE : Elsewhere  <p>NVD</p> <ul style="list-style-type: none"> Requires treatment d/t leaky newly formed vessels. 	<p>a. micro-aneurysms (Earliest).</p> <p>b. Hemorrhages (Flame shaped, dot & blot).</p> <p>c. Exudates : Lipid deposits.</p> <p>d. Cotton wool spots : Neuronal debris.</p> 
Rx :	Panretinal photocoagulation > Anti-VEGF drugs	Glycemic control

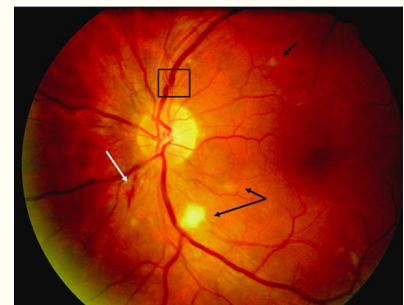
Note : Lasers in ophthalmology

Treatment modality	Laser used
Photocoagulations	Argon green
Photodisruption	Nd-YAG/Nd-glass
Photoablation	Excimer

Hypertensive Retinopathy :

Keith Wagner classification :

Grade	Retinal findings
1	Arteriolar attenuation → A : V ratio = 1 : 3 (Normal = 2 : 3)
2	Salu's sign
3	<ul style="list-style-type: none"> Bonnet sign/Gunn's sign. Flame shaped hemorrhage (White arrow). Cotton wool spots (Black arrow).
4	<ul style="list-style-type: none"> Papilledema Silver wiring.



Note : Salu's sign and Bonnet/Gunn sign are both A-V changes.

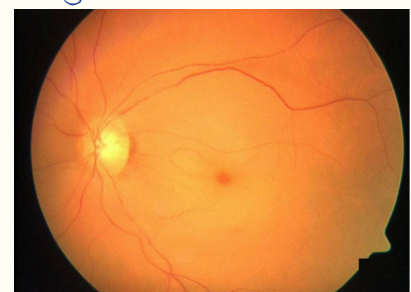
CRAO :

Causes : Atherosclerosis (m/c).

Symptoms : Sudden LOV (Emergency).

Fundus signs :

- Pale. (Retinal edema).
- Cattle tracking. (D/t blocked arteries).

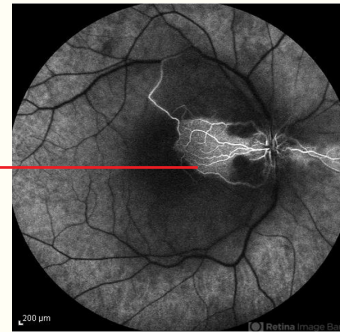


Cherry red spot at macula

Treatment :

- Ocular massage. (Dislodges emboli.)
- Sublingual isosorbide nitrate. (Vasodilation.)
- IV mannitol.
- Aspiration of aqueous. } (↓ IOP)

Cilioretinal vessels
(Supply macula)



----- Active space -----

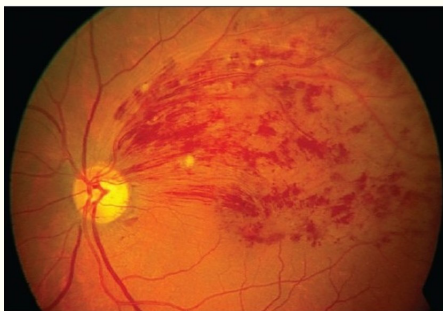FFA : Blocked blood vessels

CRVO :

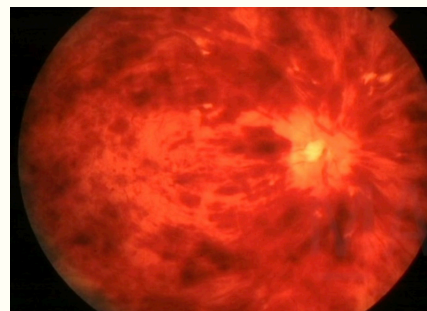	Non-ischemic	Ischemic
Pathogenesis	Stasis ↓ vasodilation ↓ ↑vascular permeability	Complete loss of blood supply ↓ Cell death
C/F	macular edema	Severe flame-shaped hemorrhages (Tomato splash fundus) Rubeosis iridis (Iris NV) → 100 day glaucoma
Rx	Intravitreal triamcinolone	Panretinal photocoagulation

BRVO :

- Branch Retinal Vein Occlusion
- m/c affects superotemporal quadrant.



BRVO : Sectoral involvement



Tomato splash fundus

Retinopathy Of Prematurity (ROP) :

Risk factors :

- Preterm infants <34 wks.
- Birth weight <1750 grams.
- Preterm infants 34-36 WOG + risk factors (RDS).

Screening of infants :

- Born ≥28wks and ≥1200g : Screen after 4 wks of birth.
- Born <28wks or <1200g : Screen within 2-3 wks of birth.

----- Active space ----- Treatment :

- Laser photocoagulation using **diode red laser** (For NV).
- Lens sparing pars plana vitrectomy (For tractional retinal detachment).

Retinal Detachment

01:02:59

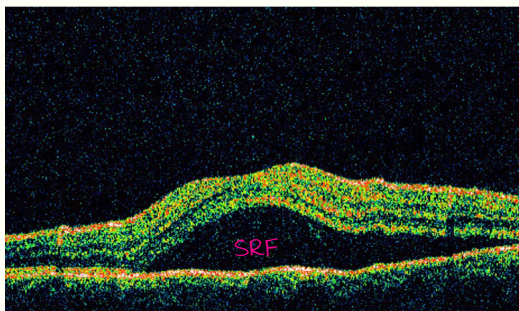
Separation of neurosensory retina from retinal pigment epithelium d/t fluid collection in subretinal space.

Types :

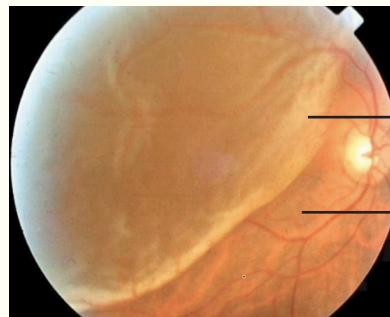
	Rhegmatogenous	Tractional	Exudative
m/c cause	Pathological myopia	Diabetic retinopathy	Choroidal melanoma
Retinal break	⊕	⊖	⊖
Syneresis (vitreous liquefaction)	⊕	⊖	⊖
Vitreo-retinal traction	⊕	⊕	⊖
Photopsia	⊕	⊖	⊖
Floater	⊕	⊖	⊖
Curtain falling before eye	⊕	⊕	⊕
Retinal surface	Convex	Concave	-
Retinal mobility	mobile	Immobile, taut	-
Signs of chronicity	<ul style="list-style-type: none"> • Retinal atrophy. • High watermarks. • Intraretinal cysts. 	Demarcation lines	
Other signs	Shaffer's sign (Tobacco dust appearance)	-	Shifting fluid
RAPD/Marcus Gunn pupil	⊕	⊕	⊕

Investigations :

IOC : **Indirect ophthalmoscopy.**



OCT : Subretinal fluid collection



Fundoscopy

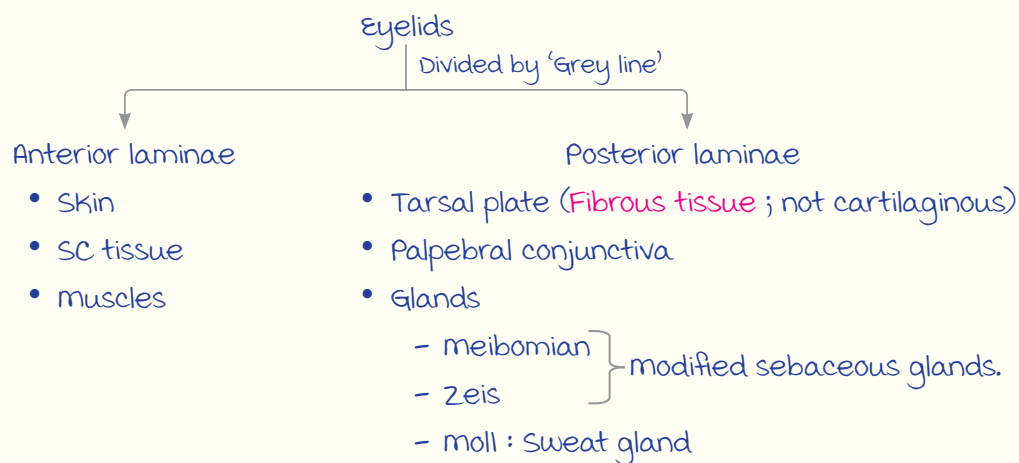
Grey detached retina
Normal attached retina

EYELIDS AND ORBIT

----- Active space -----

Anatomy of Eyelids

00:00:15




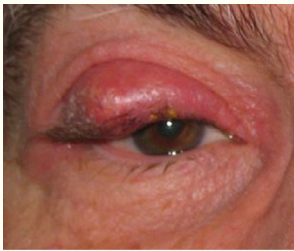
muscles of eyelid :

muscle	Nerve Supply	Action	Effect of Injury
Levator palpebrae superioris	CN III	Elevation of upper eyelid	Ptosis
muller's muscle	Sympathetic fibers		
Orbicularis oculi	CN VII	Closure of eyelids	Lagophthalmos

Eyelid Pathologies

00:03:18


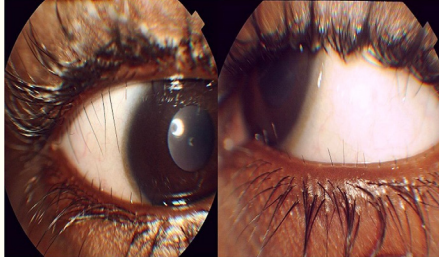
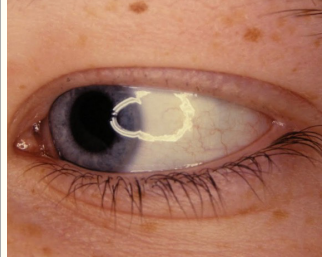
Chalazion vs. Stye/External Hordeolum :

	Chalazion	Stye/external hordeolum
Pathology	Lipogranulomatous inflammation of meibomian gland	Suppurative (S. aureus) inflammation of Zeiss gland
c/f	Painless localized (Nodular) swelling 	Painful generalized swelling 
Rx	Incision & drainage/curettage	Hot compressions

----- Active space -----


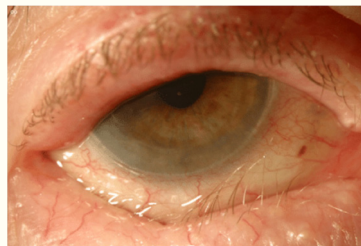
Eyelash Pathologies

00:06:30

	Trichiasis	Distichiasis	madarosis
Pathology	misdirection of cilia	Additional posterior row of eyelashes	Absent eyelashes
Appearance			
Rx	Epilation (To prevent corneal abrasion & opacity)	-	-

Lid Margin Pathologies

00:08:06

	Ectropion	Entropion
Pathology	Eversion of lid margin	Inversion of lid margin
Appearance		

Tylosis : Thickening of lid margin.

Ankyloblepharon : Fusion of upper & lower lid margins.

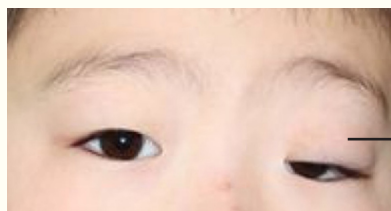Note :

Syndrome (Conjunctival disorder) : Fusion of bulbar & palpebral conjunctiva.

Congenital Ptosis :

Pathology : LPS malinsertion.

Clinical Features : Lid lag



Absent upper eyelid crease

Left eye congenital ptosis

Treatment :

----- Active space -----

Severity	Surgery
mild ptosis and good levator function	Fasanella servat operation
moderate ptosis and fair levator function	Levator resection surgery
Severe ptosis and poor levator function	Frontalis sling surgery

Surgery is done around 5 years of age.

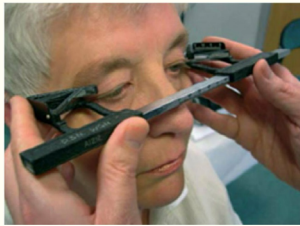
Orbital Pathologies

00:13:38

Proptosis/Exophthalmos :

Eyeball protrusion >21 mm from lateral orbital rim.

Assessment :



Hertel's exophthalmometer : Better option

Luedde's exophthalmometer : Easier to use (used in children)

Cause of proptosis	Feature
Orbital varices	<ul style="list-style-type: none"> ↑ On bending forward/ Valsalva manoeuvre u/L phleboliths on MRI
Orbital lymphangioma	↑ D/t URTI
Capillary hemangioma (Child)	↑ On crying
encephalocele (Infant)	
Carotid cavernous fistula	<ul style="list-style-type: none"> B/L, pulsatile 75% cases : Traumatic CN VI : Earliest affected nerve IOC : Digital Subtraction Carotid Angiography (DSCA)

	Cavernous sinus thrombosis	Orbital apex syndrome	Orbital cellulitis
Laterality	u/L → B/L	u/L	u/L
CN affected	III, IV, VI (earliest), V _p , V _a	II, III, IV, V _p , VI	II, III, IV, VI
a. Ophthalmoplegia	Complete (Sequential)	Complete (Concurrent)	Complete
LOV	No	Yes (D/t CN II involvement)	
Corneal sensations	Lost (D/t V ₁ involvement)	Lost (D/t V ₁ involvement)	Intact
b. Chemosis, proptosis, fever, headache	marked	minimal	marked
mastoid edema	Present	Absent	
Chronology of symptoms	a = b	a → b	b → a

V₁ : Ophthalmic n. V_a : maxillary n.

----- Active space ----- m/c causes :

	Adults	Children
u/L	Thyroid associated ophthalmopathy (Grave's disease)	Orbital cellulitis
B/L		AML (Chloroma), neuroblastoma

m/c Associations with Orbit :

- m/c cystic orbital lesions : Ductal cysts of lacrimal gland.
- m/c cystic orbital tumour : Epidermoid and dermoid.
- m/c orbital neoplasm (Paediatric age) : Epidermoid and dermoid.
- m/c orbital malignant tumor (Paediatric age) : Rhabdomyosarcoma.
- m/c orbital and periorbital tumor in children : Capillary hemangioma.
- m/c benign orbital tumour (Adults) : Cavernous hemangioma.
- m/c malignant orbital tumour (Adults) : B cell NHL (Lymphoma).
- m/c intrinsic lacrimal gland lesion/lacrimal gland epithelial neoplasm : Pleomorphic adenoma.
- m/c orbital metastasis (Paediatric age) : Neuroblastoma.
- m/c peripheral neural tumour of the orbit : Plexiform neurofibroma.
- m/c primary source of orbital metastases :
 - Breast : 42%.
 - Lung : 11% (most deaths).
 - Neuroblastoma (Paediatric age).

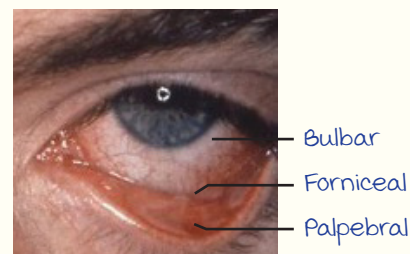
CONJUNCTIVA AND COMMUNITY OPHTHALMOLOGY

----- Active space -----

Anatomy of Conjunctiva :

Types :

- Bulbar : Lines sclera.
- Palpebral : Lines eyelids.
- Forniceal : Between bulbar & palpebral conjunctiva.



Histology :

Goblet cells :

- Present in conjunctival epithelium.
- Secretes mucin → Forms innermost layer of tear film.

Lymphatic drainage :

- medially → Submandibular lymph nodes.
- Laterally → Preauricular lymph nodes.

Conjunctivitis/Eye Flu

00:02:27

Clinical Features :

- Redness, watering.
- Stickiness, irritation.
- Foreign body sensation.
- No loss of vision.
- No pain.

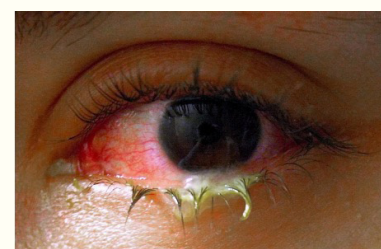Signs :

1. Discharge :

- Sticking together of eyelids in the morning.
- Colored halos.
- Types :
 - Watery : Allergies.
 - mucopurulent : Bacterial & chlamydial conditions.

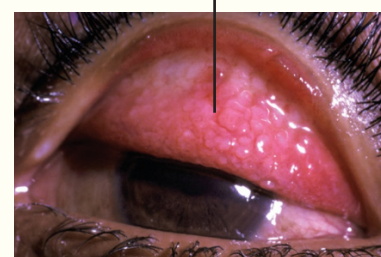
2. Papillae :

Seen in allergies & bacterial infections.



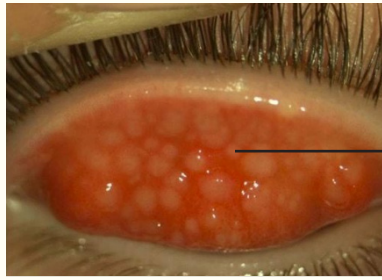
Discharge

Hypertrophied vascular cores

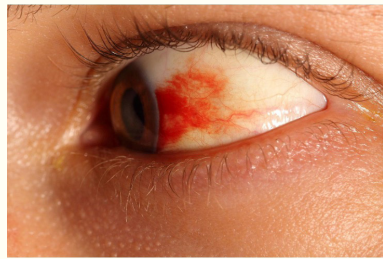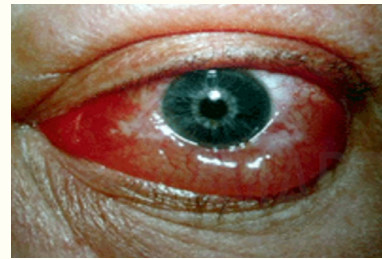


----- Active space -----

3. Follicles :

Seen in **chlamydial & viral** infections.Yellowish colored
lymphoid aggregates4. Hyperemia/congestion : **Redness.**

5. Subconjunctival hemorrhage

6. Chemosis : **Edema of bulbar conjunctiva**

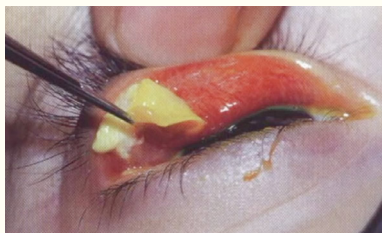Symptom Groups and Etiologies :

	Papillae	Follicles
mucopurulent discharge	Bacterial	Chlamydia
Watery discharge	Allergic	viral

Bacterial & Chlamydial Conjunctivitis

00:05:27

Bacterial conjunctivitis :



Acute pseudomembranous type

Type	Characteristics
Acute mucopurulent	Staph. aureus (m/c)
Acute/hyperacute purulent/ blennorrhoea	<ul style="list-style-type: none"> Neisseria gonorrhoeae Overhanging eyelids + copious discharge Pre-auricular lymphadenopathy
Acute membranous	Bleeds on removal
Acute pseudomembranous	Does not bleed on removal
Angular/Diplobacillary	<ul style="list-style-type: none"> Moraxella axenfeld Affects lateral canthi Rx : Tetracyclin, zinc boric acid drops

Chlamydial Conjunctivitis

00:07:21

----- Active space -----

Etiology :

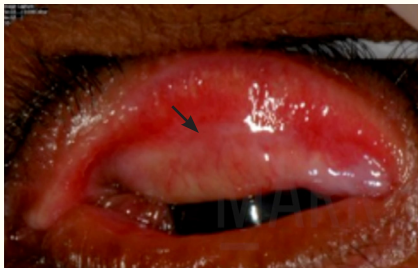Disease	Chlamydia serovar
Adult inclusion conjunctivitis	D-K
Trachoma	A, B, B _a , C
Ophthalmia neonatorum	D-K serovars, other causes

Trachoma/Egyptian Ophthalmia :

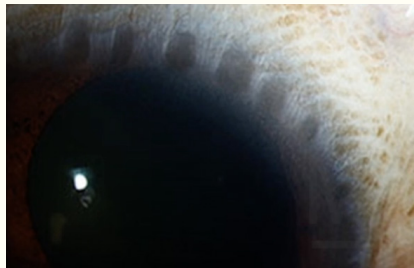
Spread : Finger, fly, fomites.

Signs :

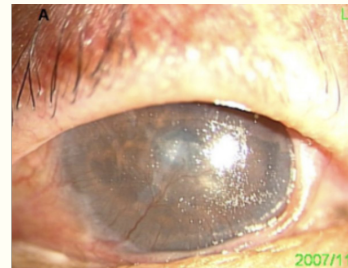
1. Sago grain follicles + papillae.
2. Arit's line : Line of cicatrization (D/t concurrent inflammation & healing).
3. Herbert's pits at limbus.
4. Pannus : Vascularization of cornea.



Arit's line



Herbert's pits



Pannus

Diagnosis : Halberstaedter-Prowazek bodies (Cytoplasmic inclusion bodies).

Treatment : SAFE strategy.

- Surgery.
- Antibiotics : Azithromycin 1 gm single dose (Stat).
- Facial cleanliness.
- Environment changes.

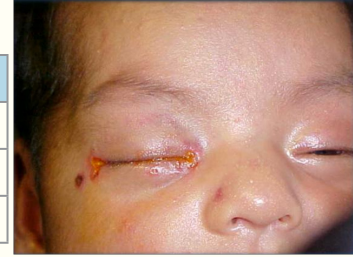Complication : Blindness

Infections → Inflammation → Scarring of eyelids → Trichiasis : Irritation of cornea by eyelashes → Corneal opacity.

----- Active space -----

Ophthalmia Neonatorum :

Onset (Hours after birth)	Cause
Within first 6 hours	Chemical (Silver nitrate) conjunctivitis
24-48 hours (most severe)	Neisseria gonorrhoeae
>1 week (m/c)	Chlamydia trachomatis (D-K)



Prevention :

- **Erythromycin** eye ointment : First 2 hrs.
- Crede's method : Obsolete (used silver nitrate).

Viral & Allergic Conjunctivitis

00:10:56

Viral Conjunctivitis :

Etiology & types :

- Adenoviral.
 - Epidemic keratoconjunctivitis (EKC).
 - Pharyngoconjunctival fever (PCF).
- Acute hemorrhagic/Apollo conjunctivitis : (**PACE**)
 - **P**icornavirus.
 - **A**denovirus.
 - **C**oxsackie A24.
 - **E**nterovirus type 70.
- HSV.
- molluscum contagiosum conjunctivitis.

Allergic Conjunctivitis :

Seasonal.

Types :

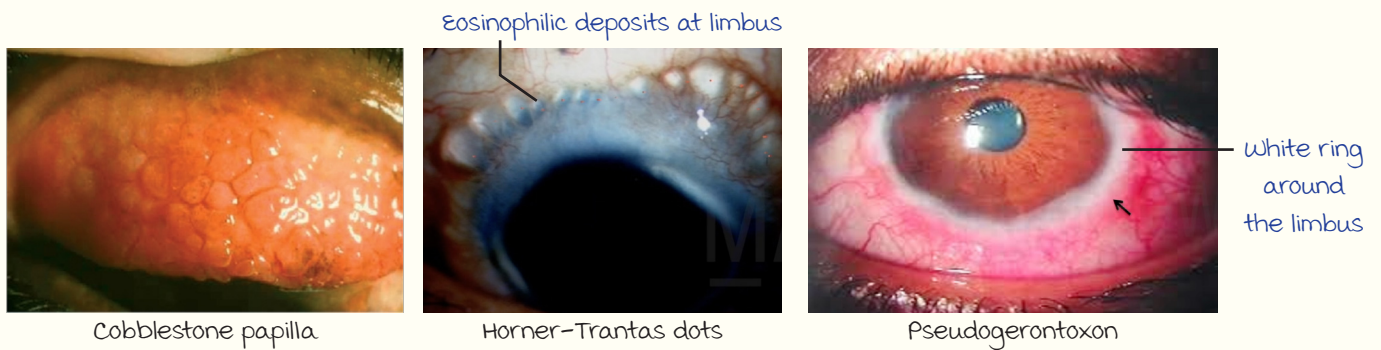
- vernal keratoconjunctivitis (VKC)/Spring catarrh.
- Atopic keratoconjunctivitis : Like VKC in adults.
- Giant papillary conjunctivitis :
 - D/t mechanical irritation : Contact lens, protruding sutures, ill-fitting prosthesis
- Phlyctenular conjunctivitis.

VKC/Spring catarrh :

- m/c in **boys** of 5-15 yrs.
- Hypersensitivity : **Type I** > 2.
- Ropy discharge : **maxwell-Lyon sign**.

Signs :

----- Active space -----



Rx :

Olopatadine (DOC) : Antihistamine + mast cell stabilizer.

+

Topical steroids : For immediate relief/acute exacerbations.

Pterygium

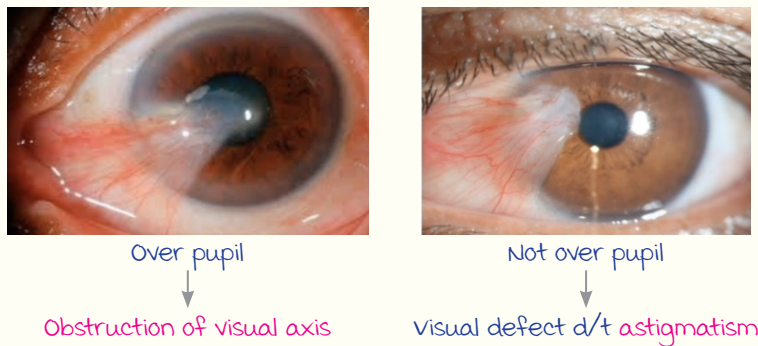
00:14:43

Triangular growth of conjunctiva over cornea.

Causes :

- Limbal stem cell deficiency.
- UV, dust, heat.

Progression :



Treatment :

Excision.

Prevention of recurrence : mitomycin C, autograft.

----- Active space -----

Community Ophthalmology

00:17:01

National Programme for Control of Blindness & Visual Impairment (NPCBVI) :

Definition of blindness :

Visual acuity $< 3/60$ in the better eye.

OR

Visual field < 10 degrees.

Goal :

↓ Prevalence of avoidable blindness to $< 0.25\%$ by 2025

(National blindness & visual impairment survey : 2015-2019).

Causes :

	Blindness	Visual Impairment $< 6/18$
≥ 50 yrs	<ul style="list-style-type: none"> Cataract (m/c) Corneal opacity 	<ul style="list-style-type: none"> Cataract (m/c) Refractive error
0-49 yrs	<ul style="list-style-type: none"> Corneal opacity (m/c) Amblyopia 	<ul style="list-style-type: none"> Refractive error (m/c) Cataract

Rashtriya Bal Swasthya Karyakram (RBSK) :

Target group : Birth to 18 yrs.

Screening : 4Ds

Covers 32 diseases under 4 categories :

- Defects at birth.
- Deficiencies.
- Diseases of childhood.
- Developmental delays.

	Target group	Screened by
Birth - 6 wks	Born at public health facilities	mobile health team
6 wks - 6 yrs	Rural areas, urban slum	ANM
6 yrs - 18 yrs	School children	Questionnaire by district hospitals